

Blood-Test Based Targeted Visualization Enables Early Detection of Premalignant and Malignant Tumors in Asymptomatic Individuals

Simon Burg^{1*}, Audrey Laure Céline Grust^{1,2}, Oliver Feyen³, Katja Failing⁴, Gamal-André Banat⁵, Johannes F Coy³, Martin Grimm⁶, Martin Gosau¹ and Ralf Smeets^{1,2}

¹Department of Oral and Maxillofacial Surgery, University Medical Center Hamburg-Eppendorf (UKE), Martinistr. 52, 20246 Hamburg, Germany

²Department of Oral and Maxillofacial Surgery, Division of “Regenerative Orofacial Medicine”, University Medical Center Hamburg-Eppendorf (UKE), Martinistr. 52, 20246 Hamburg, Germany

³Zyagnum AG, Graefenhäuser Str. 26, 64293 Darmstadt, Germany

⁴Precura Center, Heidelberger Str. 44, 64285 Darmstadt, Germany

⁵Internal Medicine, Hematology and Oncology, Chaumontplatz 1, 61231 Bad Nauheim, Germany

⁶Department of Oral and Maxillofacial Surgery, University Hospital Tuebingen, Osianderstr. 2-8, 72076, Tuebingen, Germany

*Corresponding author:

Simon Burg,
Department of Oral and Maxillofacial Surgery,
University Medical Center Hamburg-Eppendorf
(UKE), Martinistr. 52, 20246 Hamburg, Germany,
E-mail: s.burg@uke.de

Received: 02 May 2022

Accepted: 16 May 2022

Published: 20 May 2022

J Short Name: JCMi

Copyright:

©2022 Simon Burg, This is an open access article distributed under the terms of the Creative Commons Attribution License, which permits unrestricted use, distribution, and build upon your work non-commercially.

Citation:

Simon Burg, Blood-Test Based Targeted Visualization Enables Early Detection of Premalignant and Malignant Tumors in Asymptomatic Individuals. J Clin Med Img. 2022; V6(9): 1-12

Keywords:

Apo10; TKTL1; Blood-test; Early cancer screening; FDG-PET/CT

1. Abstract

Imaging is a powerful tool for the early detection of cancer and the concomitant increase of patient survival time. The low incidence of cancer in asymptomatic individuals hampers the use of imaging techniques, as the vast majority of imaging results show the absence of cancer. In a prospective, non-interventional study, 5.114 asymptomatic individuals between 50 to 70 years of age who had no personal history of cancer within the last eight years were analyzed with the so called PanTum Detect blood test, which is based on phagocytosis and elimination of tumor cells by CD14 and CD16 positive macrophages. A flow cytometry analysis of blood samples was used to detect macrophages with intracellularly tumor cell derived epitopes of biomarkers DNaseX/Apo10 and TKTL1. The increased presence of these biomarkers in macrophages allowed the identification of asymptomatic individuals eligible for further imaging. On subsequent imaging, a high proportion of this pre-selected subgroup showed abnormal tissue structures which are indicative of early cancer stages or pre-malignant structures at high risk for malignancy development. Therefore, the PanTum Detect

blood test enables the identification of asymptomatic individuals eligible for imaging.

2. Introduction

The implementation of regular screening regimen that is based on the detection of premalignant cells resulted in a dramatic 60-70% reduction in the incidence of cervical cancer [1, 2]. According to data from 2014, without any screening measures, about 3-5% of women in Germany develop cervical cancer, whereas this is the case in less than 1% of women with early detection measures [3]. Early detection of tissue alterations that are not yet malignant but are at high risk for malignancy provides the possibility of removing or monitoring them until removal is indicated, potentially preventing the onset of cancer and significantly reducing mortality [4, 5].

Regular screening measures have been established in Germany also for tumors of the colon, skin, breast, and prostate, with which about 45% of new cancer cases per year can be detected - assuming widespread and consistent adherence [6, 7]. Conversely, this means that about 55% of new cancer cases per year cannot be de-

tected with the currently established screening programs. Further developments in cancer screening should therefore aim to extend the success of cervical cancer screening to other tumor types, thus closing this «screening gap».

Our department of Oral and Maxillofacial Surgery, at the University Medical Center Hamburg-Eppendorf (UKE), is specialized in surgery of tumors of the oral cavity, tongue and neck, which are not yet covered by any early detection programs. However, early detection programs would be valuable for these tumors in particular, as they are often characterized by aggressive growth and tissue-preserving surgery, therefore carrying a high risk of recurrence [8]. In addition to the psychological burden of the life-threatening disease, patients often suffer from the consequences of the operation, which can lead to facial disfigurement and restrictions in eating and speaking. Our department is therefore particularly interested in early detection measures that would ideally allow the detection of oral cavity carcinomas at such an early stage that tissue-sparing surgery can still be performed.

In order to close the aforementioned «screening gap», an early detection procedure would be required that fulfills the following three requirements:

1. detection of many different tumor entities, since for the majority of tumor entities no established screening measures are available so far [6, 7].
2. detection of pre-malignant tumors in addition to malignant tumors - similar to the screening for cervical carcinoma. However, since the incidence of premalignant tumors increases with age [9-12], the procedure should ideally only detect tumors with a high risk of malignant transformation or at the onset of malignant transformation.
3. applicable in the field of health screening to detect tumors in premalignant or early malignant stages prior to the onset of symptoms. This requires the detection of as many malignant and premalignant tumors as possible with a high risk of transition to malignancy without generating many false positive results at the same time.

The use of imaging techniques such as ultrasound, Magnetic Resonance Imaging (MRI), Computed Tomography (CT), or positron emission tomography with the glucose analog 2-[18F] fluoro-2-deoxy-D-glucose (FDG-PET) in combination with computed tomography (FDG-PET/CT) already allows the detection of premalignant and malignant tumors. They have proven to be powerful tools for localizing and evaluating a wide variety of tumors and are widely accepted in clinical practice as the gold standard for tumor detection and localization in cases with sufficient tumor suspicion [13-15]. Their use in health screening, however, does not seem justified due to the associated costs, limited availability, and risk of radiation exposure for certain procedures.

Therefore, in order to close the «screening gap» via imaging tech-

niques, an additional selection procedure is needed so that patients with increased suspicion of premalignant or malignant tumors can be identified easily, cost-effectively, and without significant burden, and these patients are eligible to undergo appropriate imaging to confirm or eliminate the suspicion.

A screening program based on a blood test (PanTum Detect) enables a stratification for targeted imaging procedures and could fulfill all three requirements.

The PanTum Detect blood test exploits the technique of Epitope Detection in Monocytes (EDIM) utilizing the fact that activated monocytes/macrophages (CD14+/CD16+) phagocytose tumor cells and contain tumor proteins intracellularly [16-20]. These can be detected by flow cytometry from peripheral blood samples using specific antibodies. The PanTum Detect blood test screens for the presence of two biomarkers, Apo10 (epitope of DNaseX = DNase1L1) and TKTL1 (epitope of the enzyme transketolase-like 1 (TKTL1)) in CD14+/CD16+ activated monocytes (macrophages) by flow cytometry [19-22]. Apo10 is an epitope of the endonuclease DNaseX, accumulating in the nucleus of abnormal proliferating cells. The presence of the Apo10 epitope in these cells is indicative of an inhibited apoptosis. The accumulation of the Apo10 epitope is being used as a marker of inhibited apoptosis and thereby enables the detection of cells with abnormal proliferation – the first and general step towards tumor formation and growth. Apo10 epitope accumulation can be seen in all types of solid and nonsolid tumor cells [19, 20, 23, 24]. TKTL1 is a biomarker for activated cell division, increased ribose-5-phosphate formation, high proliferation, increased glucose uptake and lactic acid production even in the presence of oxygen (aerobic glycolysis / Warburg effect), invasive growth and metastasis [25-30] and tumors executing immunosuppression [31-33].

A pilot study with 1976 subjects (Ethics Committee of the Medical Association of Hessen, Frankfurt, Germany, approval number: 2020-1981-evBO) was conducted to determine the proportion of PanTum Detect test positives under realistic conditions in a population of asymptomatic subjects between 50 and 70 years of age without known cancer within the last eight years. In case of a positive blood test result, participants were recommended to follow up with FDG-PET/CT imaging (not part of the study), revealing clear evidence of malignant tumors in many cases. Particularly impressive was the case of a 53-year-old female patient (former smoker) with no complaints or symptoms and a positive blood test result. FDG-PET/CT showed an urgent suspicion of lung carcinoma parahilar in the right upper lobe. Surgical resection and subsequent histologic examination revealed a typical stage I A2 carcinoid of the right upper lobe, which was completely excised, and no further therapy was required.

Aim of the present prospective, interventional study was to verify the findings of the preliminary study and to investigate the suitability of the PanTum Detect blood test for pre-selecting such asymp-

tomatic individuals with a high probability of malignant tumors in subsequent imaging. In contrast to the pilot study, MRI was additionally used as an imaging modality in the PanTum Detect study.

3. Material and Methods

3.1 Patients and Study Design

Prospective, multicenter, interventional study (ZYA-IVD-20202) conducted since 13 July 2021 under scientific direction of R.S., University Medical Center Hamburg-Eppendorf. Goal was to enroll 5000 healthy subjects, between 50 and 70 years of age with no personal history of cancer within the last eight years. Age- and gender-distribution, health condition and family history of cancer were evaluated to characterize the population. The participants were enrolled through the Precura Center, Darmstadt, Germany, and the University Medical Center Hamburg-Eppendorf, Germany. After being informed of the scope and potential outcome of the study, all applicants were required to provide written informed consent. Exclusion criteria were, due to their influence on immune competence: current cancer indications or suspected cancer; treatment with immunostimulants like granulocyte-macrophage colony-stimulating factor, corticosteroids; acute febrile or herpes zoster diseases; vaccinations or intake of contrast agents within the last four weeks prior to blood draw; amygdalin intake, surgeries, or serious injuries within the last eight weeks prior to blood draw.

3.2 Blood Collection and Conduct of the Blood Test

Blood collection had to take place at the earliest 60 minutes after the last meal. At least 2 ml of EDTA whole blood per subject was collected in a sterile manner by venipuncture using a Sarstedt Monovette 2.7 ml EDTA. Shipping to the laboratory was undertaken by a transport service provider specialized in shipping blood samples, and the samples were stored at room temperature (15-25 °C). Staining was performed with antibodies CD14 (OFC-14D), CD16 (Hi-16a), Apo10 (clone JFC 19X63) and TKTL1 (clone JFC12T10), and flow cytometry analysis took place within 36 hours after blood collection at PreMed Labor GmbH, Pfungstadt, Germany with a BD FACSCanto™ II Flow Cytometry (Canto) operating software BD FACSDiva™ software version 8.0.3 and version 9.0.1. Test results were considered positive if the sum of the two individual scores for Apo10 and TKTL1 reached or exceeded the threshold of 260 and, in addition, the Apo10 individual score was ≥ 140 (hereafter total score). Subjects with a positive test result and a Prostate Specific Antigen (PSA) level in the normal range underwent subsequent MRI examination and FDG-PET/CT examination. Subjects with an elevated PSA level were referred to a specific Prostate MRI. Subjects with a negative test result were followed up after 12 months to obtain information on possible cancer diagnoses (e.g., in the context of other cancer screening measures and due to symptoms) within this period to assess the sensitivity of the procedure.

3.3 Imaging

For MRI examination, subjects were instructed to fast for at least 4 hours prior to the examination and to remove all metallic objects. An MRI of the abdomen was performed, followed directly by an MRI of the head and neck (native without contrast) in the same device after repositioning. As a standard, a 3 Tesla device with the highest resolution was used, for patients over 130 kg body weight and/or severe claustrophobia, it was possible to switch to a 1.5 Tesla device with a larger diameter in the same practice. At Die Radiologen Weiterstadt, a GE Nr 750 (3T) or a Siemens Aera (1.5T) was used. The following sequences were created: Abdomen: T2 axial single shot 5 mm 2-3 blocks; T2 coronal FS propeller; T2 sagittal single shot; T1 axial 5 mm 2-3- blocks; axial DWI 2 blocks / Head: Flair axial; T2 sagittal; T1 coronal; DWI axial / Neck: STIR coronal; T2 FS axial; T2 sagittal; T1 coronal. At Radiologie am Rathausmarkt Hamburg, a Siemens-Skyra (3T) or Sola (1.5 T) is used; analog sequences were acquired. Additional contrast agent administration was not required.

FDG-PET/CT was performed at the Nuclear Medicine / PET-CT Center, DKD HELIOS Clinic Wiesbaden and Radiologische Allianz Hamburg.

For FDG-PET/CT assessments subjects were instructed to fast for at least 6 hours prior to the scan and to avoid strenuous exercise 48 hours in advance. Subjects with diabetes were also instructed about taking medication before the scan. Blood glucose levels were controlled before intravenous administration of F18-FDG (1-2 MBq/kg BW, maximum 200 MBq) with a cut-off of ≤ 200 mg/dL. Following an uptake-phase (60 to 90 minutes) a low-dose CT was performed from the base of the skull to the thighs without iodinated contrast. CT images were obtained with 1-2 mm slice thickness, 100-120 kV and variable mAs based on weight (quality reference 50-80 mAs, iterative reconstruction). Subsequent PET images were acquired in 3D mode and obtained from the base of the skull to mid-thigh (8 to 10 bed positions, 2 to 3 minutes per bed position depending on weight, or by continuous acquisition over 20 minutes ('FlowMotion')). The PET data were reconstructed using «time of flight» and «point spread function modeling». Weakness correction was performed by the CT data set. Multiplanar (axial, coronal and sagittal) reconstructions and a MIP were generated, in addition axial CT and PET images were fused.

3.4 Evaluation and Categorization of the Findings

Blood test, MRI and PET/CT data were evaluated by a multidisciplinary review committee consisting of experienced radiologist and oncologist (K.F., A.B., A.W., J.H., A.G., S.B., M.O.), who were led by the principal investigators. Test findings were categorized by the tumor board with respect to anamnesis and family history as follows: 1. no suspicion of tumor, 2. situation unclear, 3. suspicion of malignant tumor. A closer look at the cases in the

category «unclear situation» revealed that a differentiated classification regarding the risk potential for malignancy seemed reasonable. Therefore, the cases within the category «situation unclear» were additionally assigned to the following subcategories: a. benign tumor, b. morphologically conspicuous without glucose uptake, and c. morphologically conspicuous with glucose uptake.

3.5 Statistical Analysis

Statistical analyses have been performed using SAS software (Version 9.4; SAS Institute; Cary NC, USA). This Interim analysis followed pre-specified principles, outlined in a Statistical Analysis Plan (SAP). Data has been descriptively evaluated, presenting means, standard deviations, medians, quartiles, minima and maxima for continuously scaled data, or absolute and relative (percentage) frequencies for categorically scaled data, respectively.

4. Results

Overall, 5114 subjects were included in the study. In 50 cases, blood samples could not be analyzed due to transport damage or an insufficient macrophage count. The study analysis included data of 5064 participants with a valid PanTum Detect blood test results, with 57% of participants being female and 43% male. Participants were in mean (SD) 56.8 ± 5 years, with about 72.6% being between 50 and 59 years and 27.4% between 60 and 70 years. 3921 of 5048 (77.7%) of participants reported a family history

of tumor diseases. The age adjusted Charlson Comorbidity Index (CCI) was moderate (1-2) in the vast majority (92.2%) of participants, 7.5% had severe CCI scores of 3-4 and 0.3% of participants had a CCI Score of ≥ 5 .

Based on the cut-off value of ≥ 260 for the combined PanTum score and, in addition, an Apo10 score ≥ 140 , the proportion of test positive subjects (n=186) was 3.67%. The proportion of test positives increased from 3.55% (CCI 1-2) to 5.34% (CCI ≥ 3).

For 151 patients with positive PanTum test results, imaging results and tumor board assessment were available. Reasons for drop-out were patients refusing MRI or PET/CT or postponing of imaging to a later date due to illness, vacation, etc. For these test positives, imaging and tumor board evaluation revealed „no suspicion of tumor“ in 9 subjects, „suspicion of tumor“ in 27 subjects, and „situation unclear“ in 115 subjects. A more differentiated categorization of this last group revealed evidence of a) benign tumor in 18 subjects, b) morphologically conspicuous premalignant tumor without glucose uptake in 17 subjects, and a morphologically conspicuous premalignant tumor with glucose uptake in 80 subjects. In total, premalignant and malignant tumors were detected in 32 localizations (Figures 1 to 4). In case of subjects with more than one premalignant or malignant tumor detected in different locations, these were included in the respective graphs.

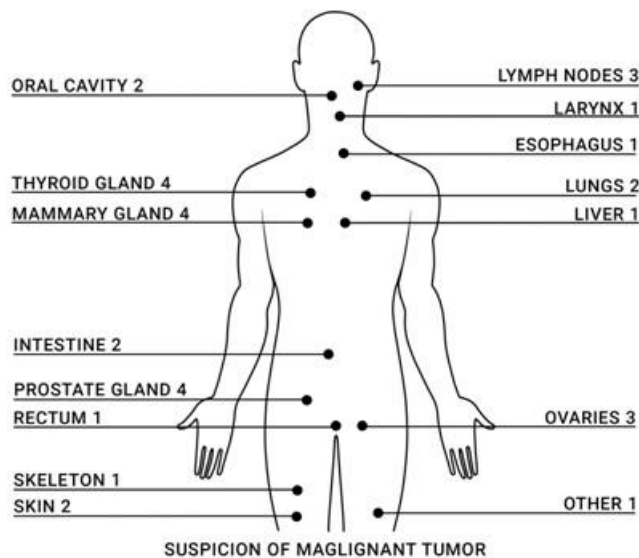


Figure 1: Localization of malignant tumors detected with PanTum Detect and subsequent imaging.

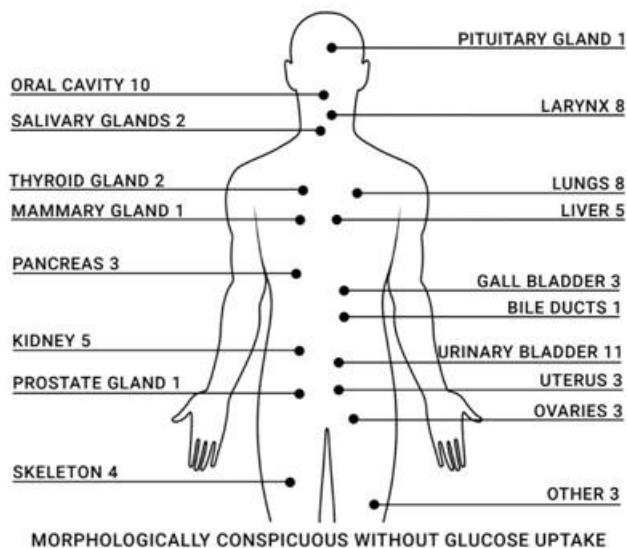


Figure 2: Localization of morphologically conspicuous premalignant tumors without glucose uptake detected with PanTum Detect and subsequent imaging.

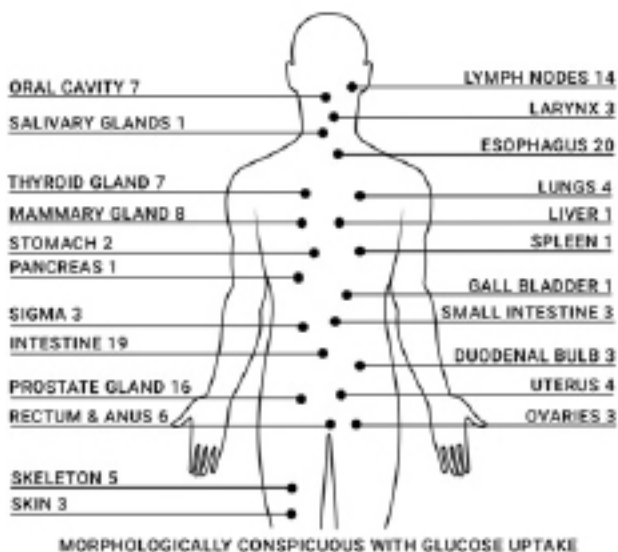


Figure 3: Localization of morphologically conspicuous premalignant tumors with glucose uptake detected with PanTum Detect and subsequent imaging.

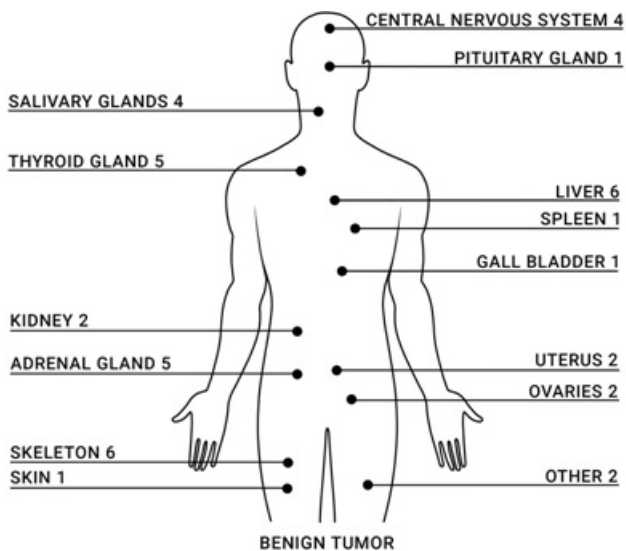


Figure 4: Localization of benign tumors detected with PanTum Detect and subsequent imaging.

5. Discussion

The aim of the study was to investigate the suitability of the PanTum Detect blood test for pre-selection of asymptomatic individuals with a high probability of the presence of a malignant tumor on subsequent imaging. For that purpose, it was intended to evaluate whether the proportion of individuals testing positive with malignant tumor on subsequent imaging is high enough to justify the use of these procedures.

The presented results demonstrate that the combination of the PanTum Detect blood test and subsequent imaging (in case of test positives) is capable of indicating a suspected malignant tumor. Additionally, in other subjects with positive PanTum Detect results, evidence of premalignant tumor was detected on subsequent imaging. A more detailed analysis of this group demonstrated that, based on FDG-PET/CT findings, a differentiation regarding their risk of tumor progression appears to be feasible. In our opinion, these findings are groundbreaking, therefore we decided to present them in this publication prior to the completion of the study.

With regard to the detection of malignant tumors, in this study, 27 of the 151 subjects with a positive PanTum Detect result had evidence of a malignant tumor in subsequent imaging and tumor board evaluation, corresponding to a detection rate for malignant tumors of 0.66%. Of a total of 5064 subjects, 186 showed positive PanTum Detect scores. Of these, results from PET/CT and MRI examinations were available for 81.18% (n=151) of subjects. Therefore, the calculation of the detection rate was based on 81.18% of 5064 subjects, i.e., 4111 subjects. Chan et al. determined a malignant tumor detection rate of 1.1% when FDG-PET/CT was used directly (without preselection) in an asymptomatic Asian population [15]. Detection rates of 0.7-1.5% have been reported from other cancer screening studies with more than 1000 participants using PET or PET/CT within Asian symptomatic populations [35-38]. The different detection rates are not directly comparable due to different study populations, age distributions and study design. In our study design, the detection of advanced tumor disease was largely ruled out, as subjects with symptoms and a suspicion of tumor disease were excluded. In addition, 98.8% of 5048 in our study reported attendance at established screening examinations. Thus, subjects in whom a tumor was detected during an established screening examination within the last 12 months could not participate in our study. Accordingly, due to the study design and the selected inclusion and exclusion criteria, it was expected that the incidence for the presence of malignant disease in the subject group would be lower than the incidence of new cancer cases in the overall population.

Calculations taking into account the gender and age distribution suggest an incidence of new cancer cases of 0.75 in the study group [6]. RKI incidence data were available for the age range of

50 to 69 years. Considering the sex and age distribution, the detection rate of 0.66% determined in this study thus corresponds to the statistically expected detection rate. It can therefore be assumed that the actual study objective will be achieved.

Overall, the data suggest that the detection rate which was determined in our study is within the expected range. It should be noted that in our study, due to the upstream use of the PanTum Detect test for pre-selection, only the 186 test-positive subjects required an FDG PET/CT scan to screen the study population of 5064 subjects, whereas in the study by Chan et al. all 3700 asymptomatic subjects received an FDG PET/CT scan. In addition, indications of malignant tumors of various origins were detected in different organs, including tumors for which no established early detection measures are yet available (Figure 1: Localization of malignant tumors), such as oral cavity carcinoma. The detection of tumors of various origins with the PanTum Detect blood test in combination with radiological imaging is attributable to the biomarker Apo10, which detects an epitope of DNaseX. This endonuclease executes the final step of apoptosis (programmed cell death), namely the degradation of nuclear DNA in 300 base pair fragments [39, 40]. In contrast to this, the Apo10 epitope of DNaseX accumulates in the nucleus of abnormally proliferating cells without achieving endonucleatic degradation of nuclear DNA [21, 41]. Accumulation of the Apo10 epitope in the nucleus of abnormally proliferating cells thus represents a very early event during malignant transformation of normal cells into tumor cells [20, 23, 24], and has also been demonstrated in Cervical Intraepithelial Neoplasia (CIN), cervical cancer, and Oral Squamous Cell Carcinoma (OSCC) as well [20, 21, 41]. The detection of Apo10 in macrophages as a result of phagocytosis of cells with an abnormally increased proliferation is being exploited as a Pan marker for all types of cells with abnormal proliferation. The presence of a such a biomarker for all types of cells with an abnormally increased proliferation is a prerequisite of a Pan tumor marker, therefore enabling the detection of all types of tumors. In addition to the detection of the epitope DNaseX (Apo10), an epitope of TKTL1 is also detected in macrophages in the blood. Accordingly, the PanTum Detect blood test is exploiting the detection of two different biomarkers – the Apo10 and the TKTL1 epitopes, respectively. This allows the detection of phagocytosed cells with an abnormally increased proliferation rate and phagocytosed cells with TKTL1 associated metabolic changes (metabolic transformation), which are indicative and crucial for the presence of malignant tumors. Several studies have shown that the overexpression of TKTL1 occurs in numerous cancers such as breast, lung, colon, urothelial, esophageal, liver, gastric, laryngeal, oral squamous cell carcinoma and melanoma, and is associated with a poor prognosis, invasiveness, and metastasis in many of these tumor entities [21, 28, 42-57], and as well as tumors executing immunosuppression [31-33].

In addition to the detection of malignant tumors, the detection of precancerous lesions is even more essential in terms of cancer screening, as this offers the possibility of preventing the occurrence of cancer [4, 5]. However, with increasing age, the presence of such premalignant growths [9-12] that will never progress into carcinomas also increases – accompanied by a risk of overdiagnosis or even overtherapy, which could jeopardize the benefit of a screening program. In this regard, the observation made in our study that the group of precancerous lesions can be divided into different subgroups depending on the expected risk of degeneration is groundbreaking. In this context, the biomarker TKTL1 is of particular importance, as the metabolic changes (metabolic transformation) associated with TKTL1 expression becomes measurable [26, 48, 58]. This is crucial for the transition from a premalignant to a malignant cell and correlates with an increased glucose uptake on FDG-PET/CT [19].

The importance of TKTL1 for cell division was impressively described for the first time by Li et al. [30]. With the onset of cell division, cells require additional glucose to provide energy and precursor materials for new cellular components, resulting in an increased glucose demand. The transformation of a premalignant to a malignant cell is therefore characterized by an increased glucose uptake [13, 19, 42, 59-61]. The transformation process to malignancy does not start in all cells simultaneously, but in discrete cell areas with increased TKTL1 expression. This increase in TKTL1 expression can be detected with the PanTum Detect blood test and is visible in PET/CT imaging by diffuse FDG accumulation. Feyen et al. have shown that the TKTL1 marker can be used to detect upregulation of glucose metabolism in tumor cells, which correlates with FDG PET/CT results [19]. Thus, there is a direct rationale between elevated levels of TKTL1 as a marker of metabolic transformation and transition to malignancy and the accumulation of radiolabeled glucose in tumor cells. For cervical carcinoma, it has already been shown that the level of TKTL1 expression correlates with progression from premalignant stages (cervical neoplasms) to advanced stages [62]. Research by Chiari et al. shows that there is a highly significant association between increasing levels of TKTL1 in double-positive (HR-HPV – high oncogenic risk human papillomaviruses and Pap smear – Papanicolaou smear) cervical smears and the risk of HR-HPV-related oncoprogression and suggests that TKTL1 is a robust predictive biomarker for the risk of progression of premalignant precursors [63].

Accordingly, in the present study, premalignant lesions were divided into the following three subgroups according to their expected risk of degeneration based on morphological and metabolic parameters: a) benign tumors, b) morphologically conspicuous without glucose uptake, and c) morphologically conspicuous with glucose uptake. A total of 251 premalignant lesions were found in different organs (Figure 2-4). Since the risk of progression for

benign tumors is considered to be very low, no further follow-up was recommended, and these cases were considered false-positive. Consistent observations on the presence of asymmetries were described as the most common clinical manifestations for head and neck malignancies [64-68]. Based on these findings, within the group of morphologically conspicuous tumors without glucose uptake, the risk of progression was considered by the tumor board to be so high that further investigations by specialists were strongly recommended. In morphologically conspicuous tumors that simultaneously showed increased glucose uptake on FDG-PET/CT, the risk of progression was judged even higher. Detection of tumors belonging to the two subgroups «morphologically conspicuous» (without or with glucose uptake) thus provides the opportunity to prevent the occurrence of cancer by regularly monitoring them and removing them promptly in the event of a transition to malignancy [4,5]. For both groups, imaging provided valuable information for the subjects, that positive PanTum Detect findings were considered true-positive. In particular, identification of premalignant lesions with increased glucose uptake on FDG-PET/CT appears to potentially allow detection of precisely those precursors that are in transition to malignancy. In this context, diffuse FDG enrichments in FDG-PET/CT examinations seem to reflect a coexistence of TKTL1-positive and TKTL1-negative cell areas, indicating the process of malignant transformation. This is impressively demonstrated by the case of a patient with a positive PanTum Detect result, who presented with a diffuse FDG accumulation in the prostate on the FDG-PET/CT (Figure 5a). Due to slightly elevated PSA level (5.31 ng/ml) and CA19.9 level (58.4 U/ml), a 3T high-resolution MRI scan of the prostate was subsequently performed, revealing a PI-RADS stage 5 and thus a high-grade suspicion for a malignant tumor. Also, in the case of a patient with a positive PanTum Detect result, FDG-PET/CT showed a focal FDG enhancement at the edge of an ovarian cyst, where the histological evaluation of the excised cyst confirmed the suspicion of a malignant precursor (Figure 5b).

Overall, the combination of the two markers Apo10 (impaired apoptosis; transition from healthy cell to tumor cell) and TKTL1 (metabolic transformation, transition to malignancy, tumors executing immunosuppression) aims to detect malignant and immune escaping tumors in the whole body. The determination of Apo10 as well as TKTL1 in macrophages (single score) as well as the combined value of Apo10 and TKTL1 can be further used to identify those among the group of premalignant tumors, in which a metabolic transformation and progression to malignant and immunosuppressive tumors has already begun (Figure 6). In addition to the localization of the tumor, the subsequent FDG-PET/CT imaging fulfills another important function, as it enables a differentiation between premalignant stages with and without an increased glucose uptake as a surrogate marker for high risk of switching to malignant tumors.

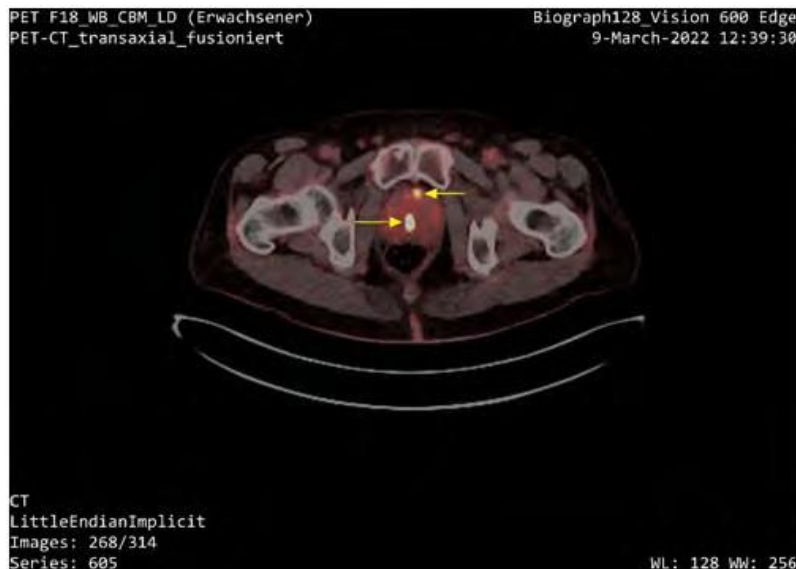

Figure 5a: FDG PET/CT image of a patient with positive PanTum Test and a slightly elevated PSA level of 5.31 ng/ml. A diffuse FDG accumulation in the prostate is visible (marked with arrows).

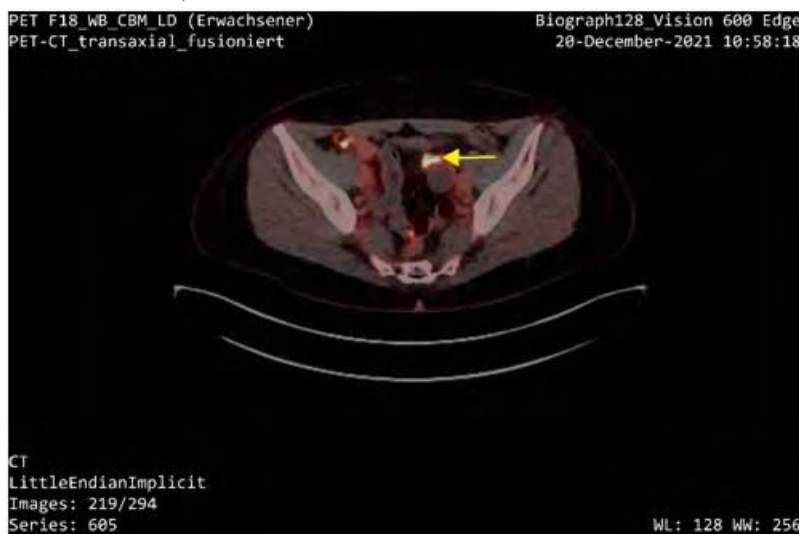

Figure 5b: FDG-PET/CT image of a patient with positive PanTum Test result showing focal FDG accumulation in the area of an ovarian cyst (marked by an arrow). Histology after excision revealed a premalignant stage.

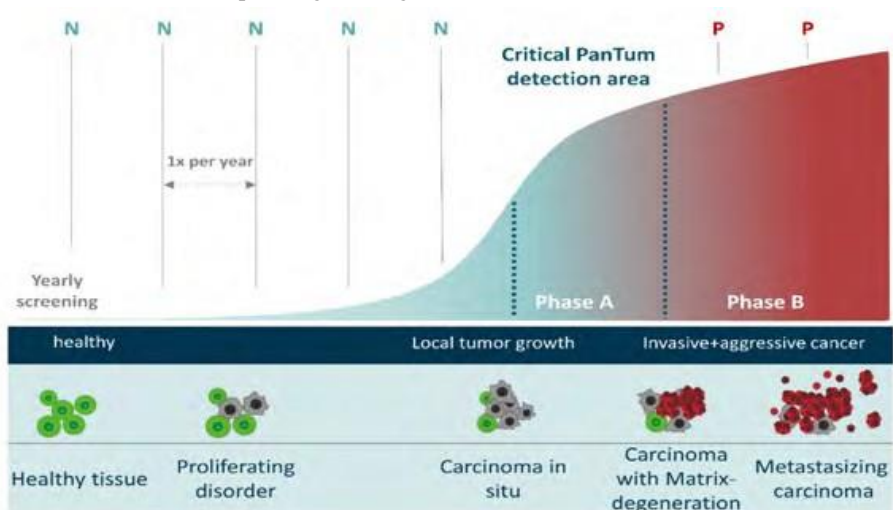


Figure 6: The PanTum Detect test is effectively used annually for cancer prevention. N- Negative test result, P- Positive test result. Top: Expression of the biomarkers Apo10 and TKTL1 with time as a function of tumorigenesis. Bottom: Schematic representation of the tissue alteration during tumorigenesis from normal tissue to proliferative disorders to cancer with matrix degeneration and metastasis. Phase A represents the critical PanTum detection area. In this phase the disease is called a “tumor”, which grows locally. In this phase, the disease is still easy to treat successfully, and the tumor can usually be removed by surgery. In phase B the disease is called “cancer”. In this phase the tumor grows more aggressively and forms metastases.

5.1 Potential of the PanTum Detect Blood Test for use in Health Screening

In general, the use of blood tests in health screening is considered critical because the proportion of false-positive cases resulting in unnecessary patient burden is considered too high [69, 70]. However, unlike other blood tests that detect biomarker concentrations directly within the blood, PanTum Detect is based on EDIM technology, which utilizes the ability of the innate immune system, developed over billions of years of evolution, to phagocytose and eliminate premalignant and malignant cells from the body by CD14+/CD16+ activated monocytes/macrophages [19, 20, 22]. These can be isolated from the blood allowing the detection of such premalignant or malignant cells that are not easily accessible via skin or mucosa. Phagocytosis of premalignant and malignant cells throughout the body including cells in solid tissue types by macrophages, thus accounting for an immunological biopsy that opens up the entire proteome of a phagocytosed cell for analysis and characterization by detecting respective epitopes that are present intracellularly in macrophages by flow cytometry. Accordingly, the biomarkers Apo10 and TKTL1 are not detected diluted in the blood, but rather concentrated in the cell volumes of the macrophages. This process has a direct positive impact on the sensitivity of the PanTum Detect blood test. At the same time, phagocytosis of cells generally occurs if they are also reliably recognized as premalignant or malignant cells by the macrophages. This endogenous process must be highly specific to prevent the elimination of healthy cells.

However, the PanTum Detect test does not provide information on tumor identity and tumor localization. Therefore, the test must always be used in combination with imaging procedures in the field of health care. This was taken into account when setting the additional threshold for the Apo10 marker to ≥ 140 , so that in the case of a positive test result, a possible tumor has already reached a size that allows detection and evaluation in imaging. The Apo10 threshold is therefore not optimized for maximum sensitivity, which automatically contributes to an increase in specificity. It can be assumed that the selection of the cut-off value and the detection of the markers Apo10 and TKTL1 in macrophages by flow cytometry should translate to the performance of the assay.

Since imaging cannot be used independently for health screening, the key question is whether the PanTum Detect blood test can identify those with reasonable suspicion of malignancy or tumor at high progression risk in an asymptomatic population so that the use of imaging is justified. This was impressively demonstrated with the data of the present study: of a total of 186 subjects with a positive PanTum Detect result, imaging results and tumor board assessment were available for 151 of those 124 subjects showed evidence of a malignant tumor or a premalignant lesion with a high progression risk in the subsequent imaging. Thus, a PPV (positive predictive value) for the PanTum Detect blood test for a suspec-

ted malignant or dangerous premalignant lesion on imaging of 82.12% is calculated. This calculation is based on 151 subjects with imaging results (PP2 population with PET/CT and MRI results). Consequently, the number of true positives considerably outweighs the number of false positives. 82.12% of subjects testing positive for the PanTum Detect test hence benefit from the use of imaging modalities such as MRI and PET/CT. In our opinion, this substantial benefit justifies the limited risks associated with a PET/CT examination.

With regard to patients, it is important that the imaging procedures following a false positive PanTum Detect blood test can reliably exclude a dangerous tumor, so that the psychological stress caused by a false positive test finding can be limited to a certain period until imaging results are available. Our results indicate that the PanTum Detect blood test could be used as a screening tool and, in combination with PET/CT and MRI, enables the detection of malignant tumors and pre-malignant lesions at a stage where, in many cases, there is a good chance for a cure.

Based on the United States Preventive Services Task Force (USPSTF) recommendations on the use of low dose computed tomography for early detection of lung cancer [71], the number of detected early-stage lung cancer increased, and so did patient survival. This strongly confirms that imaging techniques such as low dose computed tomography are important tools for an early cancer detection. Additionally, a study published by Potter et al. showed an increase in diagnosed stage I Non-Small Cell Lung Carcinoma (NSCLC) from 30.2% to 35.5% (2014 to 2018) associated with an increase in the median all cause survival of 11.9% per year within the same period [72].

The annual use of the PanTum Detect blood test could enable the identification of asymptomatic persons eligible for visualization and early detection of tumors leading to increased survival times of cancer patients. The detection of premalignant lesions could increase the survival times even more because the absence of invasive growth and immunosuppression will strongly contribute to improve the survival of patients.

The high PPV of 82.12% can be explained by the high specificity of the PanTum Detect blood test. With only 27 false positive findings from imaging (groups: no suspicion of tumor/benign tumors), a specificity of 99.3% is calculated. As described above, 4111 subjects (i.e., 81.18% of 5064 subjects) were also used as the reference value for calculating specificity, because PET/CT and MRI examinations were available for 81.18% (n=151) of the 186 subjects with positive PanTum Detect scores.

Regarding sensitivity, only an approximate estimate based on statistical data is currently feasible prior to completion of the study. A comparison of the detected suspected cases with the incidence for the annual new cancer cases indicates that most of the existing tumors were detected. It is important to emphasize that the use of

the PanTum blood test in combination with imaging modalities is intended as a complement to, and not a replacement of, existing screening methods. Thus, tumors can be detected via the established screening methods. In addition, tumors for which no screening procedures exist can be detected, which in turn consequently reduces the existing screening gap.

5.2 Limitations of the Blood Test

Like any diagnostic test, the PanTum Detect blood test has certain limitations. The number of false positives is low at (27) 0.66%. In combination with imaging, the false positive PanTum Detect findings can be classified into the given categories. If many small events contribute to an elevated Apo10, imaging will not reveal evidence of premalignant lesions. If an elevated Apo10 is caused by a larger premalignant event and accompanied by an elevated TKTL1, PET/CT imaging will reveal whether the events overlap or are separate events. Separate events also lead to false positive findings.

5.3 Integration into a Screening Program

Overall, the study results show that the PanTum Detect blood test (in the case of test positives) should always be performed in combination with subsequent imaging, since only imaging allows the localization of possible tumors and differentiation of premalignant stages with high and low progression risk. From our point of view, it therefore seems reasonable to integrate the blood test into a screening program that ensures rapid imaging examinations within a defined network in the event of a positive test result. This also helps to keep the phase of uncertainty for patients as short as possible and to quickly guide all subjects with positive PanTum Detect results to further, goal-oriented and structured diagnostics.

6. Conclusion

The study results presented here demonstrate that the PanTum Detect blood test is able to identify asymptomatic individuals eligible for imaging. This targeted imaging detected abnormal tissue structures covering the whole range of malignant transformation from benign, to premalignant and to malignant structures. By choosing certain cut-off levels for single and combined scores for the biomarkers Apo10 and TKTL1 in macrophages in the blood, it was possible to select a window of detection with low amounts of structures indicative of premalignant structures and a high percentage of structures indicative of premalignant and malignant structures. Within the detected group of premalignant structures, a subgroup could be identified by increased glucose uptake in FDG-PET/CT indicating a metabolic switch which may reflect the statu nascendi development of malignancy and therefore could be indicative for high risk of progression. In the future, a follow up of benign and premalignant structures and their possible transition to malignant structures can be used to optimize the cut-off levels for the single and combined scores for Apo10 and TKTL1. Similar to the successful reduction of cervical cancer based on premalignant cells (CIN), the detection of premalignant tissue on imaging after a positive Pantum Score can also contribute to a massive reduction

in cancer-related deaths. The observed distribution of images indicative of benign, premalignant and malignant structures confirms that the applied cut-off values for the PanTum Detect blood test is suitable for pre-selecting such asymptomatic individuals with a high probability of malignant tumors in subsequent imaging.

7. Conflict of Interest

Johannes F Coy is founder and shareholder of Zyagnum AG, Darmstadt, Germany as well as owner of patents granting the use of DNaseX and TKTL1 for diagnosis of cancer. Oliver Feyen is an employee of Zyagnum AG. Authors Simon Burg, Ralf Smeets, Katja Failing, Gamal-André Banat, Martin Gosau and Audrey Laure Céline Grust declare financial funding from Zyagnum AG. Martin Grimm declares no conflict of interest

References

1. Safaeian M, Solomon D. Cervical Cancer Prevention - Cervical Screening: Science in Evolution. *Obstet Gynecol Clin North Am.* 2007; 34: 739–ix.
2. Bujan Rivera J, Klug SJ. [Cervical cancer screening in Germany]. *Bundesgesundheitsblatt Gesundheitsforschung Gesundheitsschutz.* 2018; 61: 1528-35.
3. RKI. Krebs - Gebärmutterhalskrebs. Accessed 26 Apr 2022.
4. Whiting JL, Sigurdsson A, Rowlands DC, Hallissey MT, Fielding JWL. The long term results of endoscopic surveillance of premalignant gastric lesions. *Gut.* 2002; 50: 378-81.
5. Brenner H, Stock C, Hoffmeister M. Effect of screening sigmoidoscopy and screening colonoscopy on colorectal cancer incidence and mortality: systematic review and meta-analysis of randomised controlled trials and observational studies. *BMJ.* 2014; 348: g2467.
6. Krebs in Deutschland für 2017/2018. 13th edition. Berlin: Robert Koch-Institut (Ed.) und die Gesellschaft der epidemiologischen Krebsregister in Deutschland e.V. (Ed.).
7. kbv - Kassenärztliche Bundesvereinigung. Übersicht Früherkennungsuntersuchungen. Accessed 12 Apr 2022.
8. Brocklehurst P, Kujan O, O'Malley L, Ogden GR, Shepherd S, Glennly A-M. Screening programmes for the early detection and prevention of oral cancer. *Cochrane Database Syst Rev.* 2013.
9. Neville BW, Day TA. Oral Cancer and Precancerous Lesions. *CA Cancer J Clin.* 2002; 52: 195-215.
10. Splieth CH, Sümnig W, Bessel F, John U, Kocher T. Prevalence of oral mucosal lesions in a representative population. *Quintessence Int.* 2007; 38: 23-9.
11. Kuipers EJ, Spaander MC. Natural History of Barrett's Esophagus. *Dig Dis Sci.* 2018; 63: 1997-2004.
12. Perri G, Marchegiani G, Frigerio I, Dervenis CG, Conlon KC, Bassi C, et al. Management of Pancreatic Cystic Lesions. *Dig Surg.* 2020; 37: 1-9.
13. Zhu A, Lee D, Shim H. Metabolic Positron Emission Tomography Imaging in Cancer Detection and Therapy Response. *Seminars in Oncology.* 2011; 38: 55-69.
14. Chen K, Chen X. Positron Emission Tomography Imaging of Cancer Biology: Current Status and Future Prospects. *Seminars in Oncology.*

- gy. 2011; 38: 70-86.
15. Chan H-P, Liu W-S, Liou W-S, Hu C, Chiu Y-L, Peng N-J. Comparison of FDG-PET/CT for Cancer Detection in Populations With Different Risks of Underlying Malignancy. *In Vivo*. 2020; 34: 469-78.
 16. Herwig R, Pelzer A, Horninger W, Rehder P, Klocker H, Ramoner R, et al. Measurement of Intracellular Versus Extracellular Prostate-Specific Antigen Levels in Peripheral Macrophages: A New Approach to Noninvasive Diagnosis of Prostate Cancer. *Clin Prostate Cancer*. 2004; 3: 184-8.
 17. Leers MPG, Nap M, Herwig R, Delaere K, Nauwelaers F. Circulating PSA-Containing Macrophages as a Possible Target for the Detection of Prostate Cancer A Three-Color/Five-Parameter Flow Cytometric Study on Peripheral Blood Samples. *Am J Clin Pathol*. 2008; 129: 649-56.
 18. Japink D, Leers MPG, Sosef MN, Nap M. CEA in Activated Macrophages. New Diagnostic Possibilities for Tumor Markers in Early Colorectal Cancer. *Anticancer Res*. 2009; 29: 3245-51.
 19. Feyen O, Coy JF, Prasad V, Schierl R, Saenger J, Baum RP. ED-IM-TKTL1 blood test: a noninvasive method to detect upregulated glucose metabolism in patients with malignancies. *Future Oncol*. 2012; 8: 1349-59.
 20. Coy JF. EDIM-TKTL1/Apo10 Blood Test: An Innate Immune System Based Liquid Biopsy for the Early Detection, Characterization and Targeted Treatment of Cancer. *Int J Mol Sci*. 2017; 18: 878-95.
 21. Grimm M, Schmitt S, Teriete P, Biegner T, Stenzl A, Hennenlotter J, et al. A biomarker based detection and characterization of carcinomas exploiting two fundamental biophysical mechanisms in mammalian cells. *BMC Cancer*. 2013; 13: 569-86.
 22. Saman S, Stagno MJ, Warmann SW, Malek NP, Plentz RR, Schmid E. Biomarkers Apo10 and TKTL1: Epitope-detection in monocytes (EDIM) as a new diagnostic approach for cholangiocellular, pancreatic and colorectal carcinoma. *Cancer Biomark*. 2020; 27: 129-37.
 23. Jansen N, Coy JF. Diagnostic use of epitope detection in monocytes blood test for early detection of colon cancer metastasis. *Future Oncology*. 2013; 9: 605-9.
 24. Alekseeva L, Mironova N. Role of Cell-Free DNA and Deoxyribonucleases in Tumor Progression. *Int J Mol Sci*. 2021; 22: 12246.
 25. Xu X, zur Hausen A, Coy JF, Löchelt M. Transketolase-like protein 1 (TKTL1) is required for rapid cell growth and full viability of human tumor cells. *Int J Cancer*. 2009; 124: 1330-7.
 26. Sun W, Liu Y, Glazer CA, Shao C, Bhan S, Demokan S, et al. TKTL1 is activated by promoter hypomethylation and contributes to head and neck squamous cell carcinoma carcinogenesis via increased aerobic glycolysis and HIF1 α stabilization. *Clin Cancer Res*. 2010; 16: 857-66.
 27. Diaz-Moralli S, Aguilar E, Marin S, Coy JF, Dewerchin M, Antoniewicz MR, et al. A key role for transketolase-like 1 in tumor metabolic reprogramming. *Oncotarget*. 2016; 7: 51875-97.
 28. Jayachandran A, Lo P-H, Chueh AC, Prithviraj P, Molania R, Davalos-Salas M, et al. Transketolase-like 1 ectopic expression is associated with DNA hypomethylation and induces the Warburg effect in melanoma cells. *BMC Cancer*. 2016; 16: 134.
 - Liberti MV, Locasale JW. The Warburg Effect: How Does it Benefit Cancer Cells? *Trends Biochem Sci*. 2016; 41: 211-8.
 30. Li Y, Yao C-F, Xu F-J, Qu Y-Y, Li J-T, Lin Y, et al. APC/CCDH1 synchronizes ribose-5-phosphate levels and DNA synthesis to cell cycle progression. *Nat Commun*. 2019; 10: 2502.
 31. Wang J, Li Y, Zhang C, Chen X, Zhu L, Luo T. A hypoxia-linked gene signature for prognosis prediction and evaluating the immune microenvironment in patients with hepatocellular carcinoma. *Trans Cancer Res*. 2021; 10: 3979-92.
 32. Hong S, Zhang Y, Cao M, Lin A, Yang Q, Zhang J, et al. Hypoxic Characteristic Genes Predict Response to Immunotherapy for Urothelial Carcinoma. *Front Cell Dev Biol*. 2021; 9: 762478.
 33. He X, Ding J, Cheng X, Xiong M. Hypoxia-Related Gene-Based Signature Can Evaluate the Tumor Immune Microenvironment and Predict the Prognosis of Colon Adenocarcinoma Patients. *Int J Gen Med*. 2021; 14: 9853-62.
 34. Koch-Institut. RKI - Beiträge zur Gesundheitsberichterstattung des Bundes (GBE) - Verbreitung von Krebserkrankungen in Deutschland. Accessed 20 Dec 2021.
 35. Ide M. Cancer screening with FDG-PET - ProQuest. *Q J Nucl Med Mol Imaging*. 2006; 50: 23-7.
 36. Kojima S, Zhou B, Teramukai S, Hara A, Kosaka N, Matsuo Y, et al. Cancer screening of healthy volunteers using whole-body 18F-FDG-PET scans: The Nishidai clinic study. *Eur J Cancer*. 2007; 43: 1842-8.
 37. Shibata K, Arai M, Matsuura M, Uno K, Yoshida T, Momose T, et al. Relationship of detection rate of PET cancer screening examinees and risk factors: analysis of background of examinees. *Ann Nucl Med*. 2011; 25: 261-7.
 38. Minamimoto R, Senda M, Jinnouchi S, Terauchi T, Yoshida T, Murano T, et al. The current status of an FDG-PET cancer screening program in Japan, based on a 4-year (2006–2009) nationwide survey. *Ann Nucl Med*. 2013; 27: 46-57.
 39. Coy JF, Velhagen I, Himmele R, Delius H, Poustka A, Zentgraf H. Isolation, differential splicing and protein expression of a DNase on the human X chromosome. *Cell Death Differ*. 1996; 3: 199-206.
 40. Shiokawa D, Matsushita T, Shika Y, Shimizu M, Maeda M, Tanuma S. DNase X Is a Glycosylphosphatidylinositol-anchored Membrane Enzyme That Provides a Barrier to Endocytosis-mediated Transfer of a Foreign Gene *. *J Biol Chem*. 2007; 282: 17132-40.
 41. Coy J. Compounds and Methods for Detection of Carcinomas and Their Precursor Lesions. 2006; WO2003EP51028 20031216; EP20020102814 20021218.
 42. Langbein S, Zerilli M, zur Hausen A, Staiger W, Rensch-Boschert K, Lukan N, et al. Expression of transketolase TKTL1 predicts colon and urothelial cancer patient survival: Warburg effect reinterpreted. *Br J Cancer*. 2006; 94: 578-85.
 43. Staiger WI, Coy JF, Grobholz R, Hofheinz R-D, Lukan N, Post S, et al. Expression of the mutated transketolase TKTL1, a molecular marker in gastric cancer. *Oncol Rep*. 2006; 16: 657-61.
 44. Földi M, Stickeler E, Bau L, Kretz O, Watermann D, Gitsch G, et al. Transketolase protein TKTL1 overexpression: A potential biomarker

- and therapeutic target in breast cancer. *Oncol Rep.* 2007; 17: 841-5.
45. Krockenberger M, Honig A, Rieger L, Coy JF, Sutterlin M, Kapp M, et al. Transketolase-like 1 expression correlates with subtypes of ovarian cancer and the presence of distant metastases. *Int J Gynecol Cancer.* 2007; 17: 101-6.
 46. Völker H-U, Scheich M, Schmausser B, Kämmerer U, Eck M. Overexpression of transketolase TKTL1 is associated with shorter survival in laryngeal squamous cell carcinomas. *Eur Arch Otorhinolaryngol.* 2007; 264: 1431-6.
 47. Schultz H, Kähler D, Branscheid D, Vollmer E, Zabel P, Goldmann T. TKTL1 is overexpressed in a large portion of non-small cell lung cancer specimens. *Diagn Pathol.* 2008; 3: 35-9.
 48. Langbein S, Frederiks WM, zur Hausen A, Popa J, Lehmann J, Weiss C, et al. Metastasis is promoted by a bioenergetic switch: New targets for progressive renal cell cancer. *Int J Cancer.* 2008; 122: 2422-8.
 49. Krockenberger M, Engel JB, Schmidt M, Kohrenhagen N, Häusler SFM, Dombrowski Y, et al. Expression of Transketolase-like 1 Protein (TKTL1) in Human Endometrial Cancer. *Anticancer Res.* 2010; 30: 1653-9.
 50. Kayser G, Siene W, Kubitz B, Mattern D, Stickeler E, Passlick B, et al. Poor outcome in primary non-small cell lung cancers is predicted by transketolase TKTL1 expression. *Pathology.* 2011; 43: 719-24.
 51. Diaz-Moralli S, Tarrado-Castellarnau M, Alenda C, Castells A, Cascante M. Transketolase-Like 1 Expression Is Modulated during Colorectal Cancer Progression and Metastasis Formation. *PLoS One.* 2011; 6.
 52. Schwaab J, Horisberger K, Ströbel P, Bohn B, Gencer D, Kähler G, et al. Expression of Transketolase like gene 1 (TKTL1) predicts disease-free survival in patients with locally advanced rectal cancer receiving neoadjuvant chemoradiotherapy. *BMC Cancer.* 2011; 11: 363.
 53. Song Y, Liu D, He G. TKTL1 and p63 are biomarkers for the poor prognosis of gastric cancer patients. *Cancer Biomark.* 2015; 15: 591-7.
 54. Li J, Zhu S-C, Li S-G, Zhao Y, Xu J-R, Song C-Y. TKTL1 promotes cell proliferation and metastasis in esophageal squamous cell carcinoma. *Biomed Pharmacother.* 2015; 74: 71-6.
 55. Shi Z, Tang Y, Li K, Fan Q. TKTL1 expression and its downregulation is implicated in cell proliferation inhibition and cell cycle arrest in esophageal squamous cell carcinoma. *Tumour Biol.* 2015; 36: 8519-29.
 56. Ahopelto K, Böckelman C, Hagström J, Koskensalo S, Haglund C. Transketolase-like protein 1 expression predicts poor prognosis in colorectal cancer. *Cancer Biol Ther.* 2016; 17: 163-8.
 57. Grimm M, Kraut W, Hoefert S, Krimmel M, Biegner T, Teriete P, et al. Evaluation of a biomarker based blood test for monitoring surgical resection of oral squamous cell carcinomas. *Clinical Oral Investigations.* 2016; 20: 329-38.
 58. Vander Heiden MG, Cantley LC, Thompson CB. Understanding the Warburg Effect: The Metabolic Requirements of Cell Proliferation. *Science.* 2009; 324: 1029-33.
 - Downey RJ, Akhurst T, Gonen M, Vincent A, Bains MS, Larson S, et al. Preoperative F-18 Fluorodeoxyglucose-Positron Emission Tomography Maximal Standardized Uptake Value Predicts Survival After Lung Cancer Resection. *J Clin Oncol.* 2004; 22: 3255-60.
 60. Hu L-H, Yang J-H, Zhang D-T, Zhang S, Wang L, Cai P-C, et al. The TKTL1 gene influences total transketolase activity and cell proliferation in human colon cancer LoVo cells. *Anticancer Drugs.* 2007; 18: 427-33.
 61. Lange CA, Tisch-Rottensteiner J, Böhringer D, Martin G, Schwartzkopff J, Auw-Haedrich C. Enhanced TKTL1 expression in malignant tumors of the ocular adnexa predicts clinical outcome. *Ophthalmol.* 2012; 119: 1924-9.
 62. Kohrenhagen N, Voelker HU, Schmidt M, Kapp M, Krockenberger M, Frambach T, et al. Expression of transketolase-like 1 (TKTL1) and p-Akt correlates with the progression of cervical neoplasia. *J Obstet Gynaecol Res.* 2008; 34: 293-300.
 63. Chiarini A, Liu D, Rassu M, Armato U, Eccher C, Dal Prà I. Over Expressed TKTL1, CIP-2A, and B-MYB Proteins in Uterine Cervix Epithelium Scrapings as Potential Risk Predictive Biomarkers in HR-HPV-Infected LSIL/ASCUS Patients. *Front Oncol.* 2019; 9.
 64. Wankerl V. Die diagnostische Wertigkeit der retrospektiven PET-MRT-Fusion bei Kopf-Hals-Tumoren. Technische Universität München. 2014.
 65. Hilgarth M. Der aktuelle Stellenwert der Doppelkontrastpharyngographie und von Computertomographie bei der Detektion und bei der korrekten Stadienzuordnung von Tumoren des Oropharynx, Hypopharynx und des supraglottischen Larynx. Julius-Maximilians-Universität Würzburg. 2003.
 66. Guimarães AC, de Carvalho GM, Correa CRS, Gusmão RJ. Association between unilateral tonsillar enlargement and lymphoma in children: A systematic review and meta-analysis. *Crit Rev Oncol Hematol.* 2015; 93: 304-11.
 67. Tshering Vogel DW, Thoeny HC. Cross-sectional imaging in cancers of the head and neck: how we review and report. *Cancer Imaging.* 2016; 16: 20.
 68. Spini R, Cruz D, Fernández L, Juchli M. Palatine tonsil lymphoma: a pediatric case report. *Arch Argent Pediatr.* 2021; 119: e330-4.
 69. Scatena R. *Advances in Cancer Biomarkers: From biochemistry to clinic for a critical revision.* Softcover reprint of the original 1st ed. 2015 Edition. Dordrecht: Springer; 2016.
 70. Di Capua D, Bracken-Clarke D, Ronan K, Baird A-M, Finn S. The Liquid Biopsy for Lung Cancer: State of the Art, Limitations and Future Developments. *Cancers.* 2021; 13: 3923.
 71. US Preventive Services Task Force, Krist AH, Davidson KW, Mangione CM, Barry MJ, Cabana M, et al. Screening for Lung Cancer: US Preventive Services Task Force Recommendation Statement. *JAMA.* 2021; 325: 962-70.
 72. Potter AL, Rosenstein AL, Kiang MV, Shah SA, Gaissert HA, Chang DC, et al. Association of computed tomography screening with lung cancer stage shift and survival in the United States: quasi-experimental study. *BMJ.* 2022; 376: e069008.