

## Ganglion Cyst as a Rare Cause of Medial Arch of Foot Pain and Diagnostic Accuracy of MRI

Nambi GI<sup>1\*</sup>, Subarekha TB<sup>2</sup>, Salunke A<sup>3</sup> and Yasmine J<sup>4</sup>

<sup>1</sup>Plastic, Burns, Hand & Microsurgical Services, Kavın Medical Center, India

<sup>2</sup>Consultant Radiologist, Jansons Health & M.R.I., India

<sup>3</sup>Consultant Orthopaedic Onco Surgeon, Gujarat Cancer & Research Institute [GCRI], Civil Hospital Campus, India

<sup>4</sup>Registrar, D.N.B. General Surgery, Kavın Medical Center, India

### \*Corresponding author:

Nambi GI,  
Plastic, Burns, Hand & Microsurgical Services,  
Kavın Medical Center, Perundurai road,  
Erode - 638011, Tamilnadu, India

Received: 02 Jan 2024

Accepted: 18 Jan 2024

Published: 25 Jan 2024

J Short Name: JCM I

### Copyright:

©2023 Nambi GI, This is an open access article distributed under the terms of the Creative Commons Attribution License, which permits unrestricted use, distribution, and build upon your work non-commercially.

### Citation:

Nambi GI, Ganglion Cyst as a Rare Cause of Medial Arch of Foot Pain and Diagnostic Accuracy of MRI. J Clin Med Img. 2023; V7(9): 1-3

### Keywords:

Foot arch pain; Ganglion cyst; Accessory navicular bone; Tibialis posterior tendonitis

### 1. Abstract

A rare cause of foot pain is described in which the diagnostic accuracy of the MRI proved vital in pinpointing the location of the aetiology and subsequently in corrective surgery.

### 2. Introduction

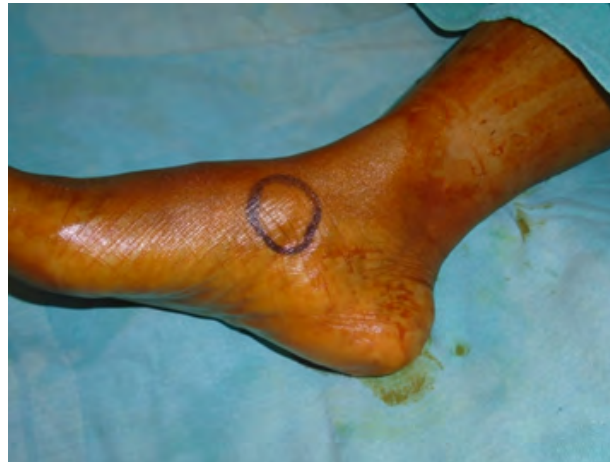Foot arch pain is a common clinical condition, and its causes depend up on the age, occupation, medical co morbid conditions and trauma. An accurate diagnosis can be made only with the help of radiological investigation.

MRI has emerged as work horse mode of investigation in diagnosing the cause of foot pain in majority of non-traumatic conditions and one such case of chronic pain of a rare non traumatic aetiology which was diagnosed accurately with MRI and successfully managed with surgery is presented in this article.

### 3. Case Report

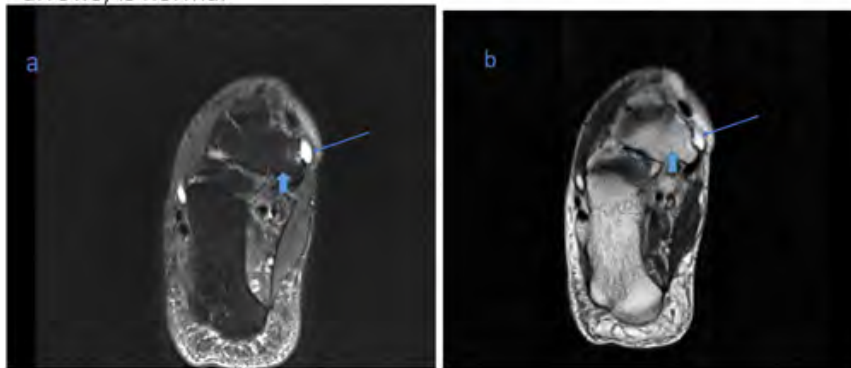
A 34-year-old woman presented with persistent pain over her right foot arch since last two years. The pain was continuous, aggravated with movements and subsided with rest. Over the course of time before she presented in our clinic, she was advised with

physiotherapy, special footwear and topical medications but none of it was effective. On examination, she was normally built with good physique and there were no medical co morbidities. The right foot configuration was normal and neurovascular assessment of the foot was also normal. There was one focal area of pain over the arch of foot measuring about 1 x 1 cm (Figure 1). The pain was dull aching in nature and was excruciating on application of pressure. Clinically, a differential diagnosis of tibialis posterior tendonitis, accessory navicular bone or interosseous bone cyst was made and she was advised MRI for confirmation. The MRI findings revealed an unexpected cause of pain (Figures 2a - 2d), which was a cystic lesion in the interspace between the navicular bone and the distal part of the tibialis posterior tendon. Under spinal anaesthesia and tourniquet control, the lesion was approached through the layers of skin and soft tissue and was found to be a ganglion cyst which was present in the exact location as shown by the MRI and it was excised completely. The MRI findings were confirmed during surgery (Figure 3) and thus underlying its diagnostic significance. The patient was pain free after excision of the ganglion cyst and is on regular follow up.



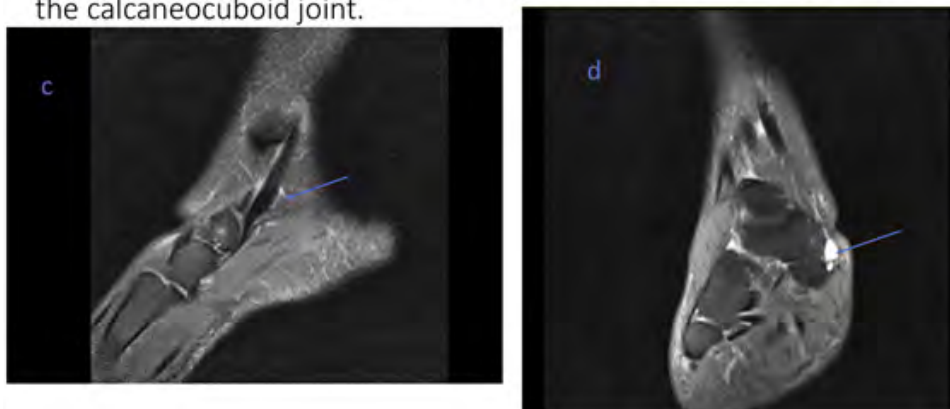
**Figure 1:** Focal area of pain over the medial arch of foot

Axial PDFS (a) and T2 (b) images of the ankle show a well defined high signal lesion (blue arrows) at the medial aspect of the naviculum anterior to the posterior tibial tendon attachment site. Navicular bone (blue block arrows) is normal



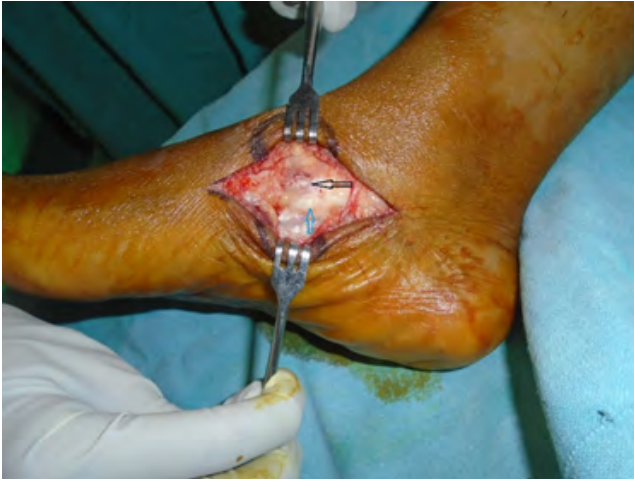**Figures 2a & 2b:** Axial PDFS (2a) & T 2 (2b) images of the ankle show a well-defined high signal lesion (White arrows) at the medial aspect of the naviculum anterior to the posterior tibial tendon attachment site. Navicular bone (Blue arrow) appears normal.

Sagittal PDFS (c) image shows normal appearance of the posterior tibial tendon except for minimal tenosynovitis (arrow) coronal PDFS (d) image shows that the cyst (arrow) does not extend into the calcaneocuboid joint.



**Figure 2c:** Sagittal PDFS image shows normal appearance of posterior tibial tendon except for minimal tenosynovitis (White arrow)

**Figure 2d:** Coronal PDFS image shows that the cyst (White arrow) does not extend in to the calcaneo cuboid joint



**Figure 3:** Intra operative image showing the ganglion cyst (Black arrow) lying deeper to the tendon of tibialis posterior (Blue arrow)

#### 4. Discussion

Pain in the arch of foot is a common condition and is associated with aging, weight gain, flat foot, inflammatory conditions of the tibialis posterior tendon and medial plantar nerve compression neuropathy. Irrespective of the causative factor, an accurate diagnosis is required to make the patient pain free and reduce the morbidity and MRI has emerged as the first-choice investigation owing to its versatility and non-invasiveness. Rare causes of foot arch pain reported in the literature includes accessory navicular bone [1], navicular bone fracture [2], middle cuneiform stress fracture [3] and pressure effects due to space occupying lesions [4]. Although rare, the most common benign space occupying lesions are the ganglion cysts. They are masses filled with gelatinous material and are commonly seen in hand and wrist. Exact etiology of the condition is not known, and they present as painless lumps. Rarely may they become painful due to compression effect over the nearby structures [5]. Depending up on the structure that is compressed, the nature and the severity of the pain varies. Majority of these lesions are diagnosed clinically while a few cases require radiological investigations to aid in the diagnosis and treatment. Management of the ganglion cysts includes surgical excision and non-surgical methods such as direct aspiration or aspiration under image guidance. The drawback of the non-surgical management is the high rate of recurrence.

In this case, clinically though a differential diagnosis was made, MRI enabled us to make an accurate diagnosis and localization of the lesion and successfully manage it with surgical excision. The ganglion cyst was located in the interspace between the navicular bone and the distal part tibialis posterior tendon causing a low-grade tendinitis along with pressure effects in the narrow interspace causing continuous pain. Owing to the non-invasive nature of the MRI, the patient was convinced about the underlying pathology and readily consented for surgery enabling a successful outcome.

#### 5. Conclusion

To conclude, the presence of ganglion cyst in the navicular bone - tibialis posterior tendon interspace is a rare occurrence and still a rare cause for foot arch pain. In rare and doubtful cases such as this, it is better to go for MRI as primary investigative method as it is non-invasive and saves time by avoiding other less accurate diagnostic methods.

#### References

1. Choi YS, Lee KT, Kang HS, Kim EK. MR imaging findings of painful type II accessory navicular bone: correlation with surgical and pathologic studies. *Korean J Radiol.* 2004; 5(4): 274-9.
2. Abe K, Hashiguchi H, Sonoki K, Iwashita S, Takai S. Tarsal Navicular Stress Fracture in a Young Athlete: A Case Report. *J Nippon Med Sch.* 2019; 86(2): 122-5.
3. Krebs P, Borchers J. A Middle Cuneiform Stress Fracture in an Adolescent Athlete: A Case Report and Literature Review. *Clin Med Insights Arthritis Musculoskelet Disord.* 2019; 12: 1179544119878712.
4. Chang KV, Wu WT, Özçakar L. Extra-tunnel Compression Mimicking Tarsal Tunnel Syndrome: Ultrasound Imaging for a Plantar Ganglion Cyst. *Med Ultrason.* 2018; 20(4): 540-1.
5. Kim S, Kim H, Jo DI, Na SJ, Jo YS. Isolated medial plantar neuropathy caused by a large ganglion cyst diagnosed with MRI: A case report. *Int J Surg Case Rep.* 2018; 42: 200-3.