

Serendipity – When Looking for his She-Donkeys, Young Saul Unveiled his Royalty

Benharroch D*

Department of Pathology, Faculty of Health Sciences, Ben Gurion University of the Negev, Beer-Sheva, Israel

*Corresponding author:

Daniel Benharroch,
Department of Pathology, Faculty of Health
Sciences, Ben Gurion University of the Negev, Ben
Gurion Ave. 84105, Beer Sheva, Israel

Received: 20 July 2023

Accepted: 19 Aug 2023

Published: 28 Aug 2023

J Short Name: JCMi

Copyright:

©2023 Benharroch D, This is an open access article distributed under the terms of the Creative Commons Attribution License, which permits unrestricted use, distribution, and build upon your work non-commercially.

Citation:

Benharroch, Serendipity – When Looking for his She-Donkeys, Young Saul Unveiled his Royalty.

J Clin Med Img. 2023; V7(3): 1-2

Keywords:

Buccal cavity sounds; Arterial brain-stem aneurysm; serendipity

1. Abstract

A 59-years-old man, producing suckling oral sounds during several months, displayed a simultaneous brain stem aneurysm. The arterial lesion was submitted to embolization, but the buccal symptoms persisted after the manipulation. The nature of the bruit originating from the oral cavity remains void. A possible association between the two events, that from the buccal origin, as well as the brain stem aneurysmal defect, should perhaps be considered.

2. Saul and his she-donkeys

The 59-y-old man, Hertzal, started out of the blue to complain of frequent fits of suckling movements affecting the anterior buccal cavity, probably encompassing the lips, the tongue and the hard palate.

While trying to elucidate the nature of the bruits, I came across such sound effects as swallow, breaths, vocals, burps and gasps. An expanded concept, termed the Beckman oral motor protocol, was under use, among others, in the Ohio Department of Developmental Disabilities (ei@dodd.ohio.gov), together with interactive therapy services. This is believed to include several patterns like suckling, simple tongue protrusion, sucking, tongue tip elevation and munching.

Apart from noticing that the bruit pattern was very unusual for a man of his age, I can only assume that the patient might never have access to a developmental pediatrician.

Under the leverage of the patient's wife initiative, herself a nurse with a nephrologic background, he had soon consulted most physicians of concern with the above complaints, except perhaps for a specialist in developmental disabilities. Moreover, a consistent

diagnosis could not be reached. As a last effort, and since no indication was disclosed, Hertzal's wife initiated a last move. She requested and obtained the performance of a CT-scan, steered to the anterior buccal cavity.

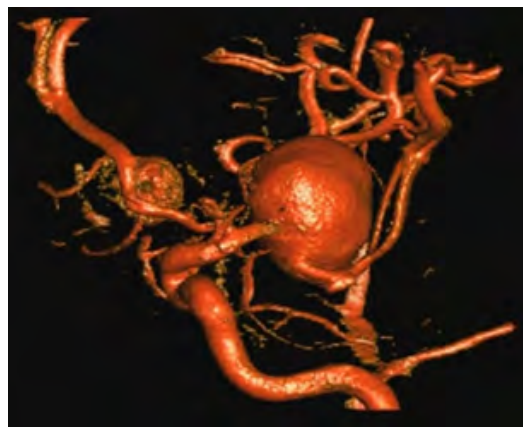


Figure 1: Aneurysm of a brain stem artery.

3. Saul found the royalty

The CT-scan was performed in such a manner, that the imaging exhibited the anterior mouth and most of the brain, as well. An incidental finding was thus disclosed in the brain stem, in the form of an arterial aneurysm [1]. Thanks to the systematic attention, indulged by his wife (TCL), Hertzal was soon submitted to a percutaneous angiography, with a therapeutic aneurysmal embolization [2], and, so far, has been spared a cerebral hemorrhage. At this point in time, while the role of the aneurysm in evoking the buccal symptomatology, should be of reduced significance, the suckling sounds persisted [3]. This might have meant a probable autonomy of the aneurysmal characteristics in contrast with the oral bruits.

This, while early in Hertzl's medical history, in which, both the buccal noises and the aneurysm seemed to be equally relevant, pointing in principle at a single cause.

4. Conclusions

The report is still missing an acceptable interpretation. The symptom of a knocking, repetitive, sound, is probably produced anteriorly in the buccal cavity. Two distinct episodes are recognized a propos the knocking sounds. One precedes the angiographic intervention; the second follows it. However, the buccal symptom does not display any difference between the two episodes. So far, we are not approaching a diagnostic resolution [4].

Among others, evidence of a kind of a tic has been contemplated. But more psychological or psychiatric data need be collected.

The tale about Shaul, displayed in the Bible, is probably one of the ancient samples of the concept of serendipity. Our character, Hertzl, or more specifically, his wife, searched extensively for the significance of the persistent knocking oral bruit. However, the exhibition of the aneurysm, while performing a CT-scan of the head, might very well have missed the arterial lesion, if the anterior oral cavity had been strictly steered by the imaging technician. Such a disregard might very well have meant a death sentence for Hertzl. But thanks to his wife, he was sentenced to life – by serendipity.

To date, a clear-cut diagnosis of the buccal noises is not accessible.

5. Acknowledgements

We thank Kibbutz Sde-Boker for their support.

References

1. Ajiboye N, Chalouhi N, Starke RM, Zanaty M, Bell R. Unruptured cerebral aneurysms: evaluation and management. *Scientific World J.* 2015; 1155: 1-10.
2. Schievink WI. Intracranial aneurysms. *New Engl J Medicine.* 1997; 336: 28-40.
3. Naggara ON, Lecler A, Oppenheim C, Meder JF, Raymond J. Endovascular treatment of intracranial unruptured aneurysms: a systematic review of the literature on safety with emphasis on subgroup analysis. *Radiology.* 2012; 236: 828-35.
4. Burns JD, Huston J III, Layton KF, Piepgras DG, Brown Jr RD. Intracranial aneurysm enlargement on serial magnetic resonance angiography: frequency and risk factors. *Stroke.* 2009; 40: 406-11.