

Traumatic Rupture of the Isthmus of the Aorta: Apropos of a Case at the Festoc Center in Bamako

Kader T, Diarra BI*, Doumbia M, Coulibaly B, Daffe S, Coulibaly B, Doucoure O, Koita S, Diallo B, Traore S, Coulibaly M, Diarra M B, Keita S, Togola B, Togo S, Ouattara MA and Yena S

Chirurgien Thoracique and Cardiovasculaire, Center Andre Festoc de Bamako, Mali

*Corresponding author:

Baba Ibrahima Diarra,
Chirurgien Thoracique and Cardiovasculaire,
Center Andre Festoc de Bamako, Mali

Received: 15 May 2023

Accepted: 22 June 2023

Published: 30 June 2023

J Short Name: JCMI

Copyright:

©2023 Diarra BI, This is an open access article distributed under the terms of the Creative Commons Attribution License, which permits unrestricted use, distribution, and build upon your work non-commercially.

Citation:

Diarra BI, Traumatic Rupture of the Isthmus of the Aorta: Apropos of a Case at the Festoc Center in Bamako. J Clin Med Img. 2023; V7(2): 1-3

Keywords:

Rupture; Trauma; Isthmus; Aorta; FESTOC; Bamako

1. Summary

Traumatic ruptures of the aorta are the most frequent vascular lesions during blunt chest trauma. They occur mainly at the level of the isthmus and follow a shear mechanism by deceleration.

We report a rare case of traumatic rupture of the aortic isthmus.

This is a 49-year-old patient with no history, referred by the traumatology department for blunt chest trauma following a traffic accident. On admission she presented with isolated chest pain. The chest X-ray showed an unfolding of the aorta. The electrocardiogram and echocardiography did not reveal any signs of myocardial contusion or valvulopathy. The thoracic CT angiography objectified a sacciform pseudo-aneurysmal image with a regular outline, measuring 37 x 16 mm opposite the isthmus. The patient had received medical treatment based on beta blockers, calcium channel blockers and analgesics. Weekly monitoring was also instituted with stability of the aneurysm on the thoracic CT angiography performed at 03 months. The search for a rupture of the aortic isthmus must be systematic in the face of any violent trauma to the thorax because it could jeopardize the patient's vital prognosis.

2. Introduction

Traumatic Aortic Rupture (TAR) is the most common vascular lesion in blunt chest trauma [4,5]. They are mainly located at the level of the isthmus and follow a shear mechanism by deceleration [4].

The rupture can be complete, involving the vital prognosis [1].

It can develop insidiously (contained rupture), in which case it is discovered at the aneurysm stage [2]. We report a case of unoperated traumatic rupture, the evolution of which is marked by the formation of an aneurysmal thrombosis.

3. Observation

This was a 49-year-old patient with no known medical or surgical history, referred by the traumatology department for blunt chest trauma associated with trauma to the left lower limb following a traffic accident. On admission, the symptomatology was made up of isolated chest pain with no visible chest lesion, with fracture localized to the lower 1/3 of the tibia, with no notion of loss of consciousness or hematemesis. The remainder of the physical examination was unremarkable.

The chest X-ray showed an unrolling of the aorta (Figure 1).

The thoracic CT angiography objectified an image of sacciform pseudoaneurysmal addition with regular outline, measuring 37 x 16 mm opposite the isthmus (Figures 2-4).

The biological assessment was normal.

The patient had benefited from a treatment based on Beta blocker (labetolol 100 mg: 0.25 to 1mg/kg/h) with an electric syringe for 48 hours in the intensive care unit, then under the oral route: Calcium channel blocker (Amlodipine 5mg, 1Cp/ jr); IPP (Pantoprazole 40 mg, 1 tab/day); Analgesic (Tramadol tab, 1 tab/08h) Weekly monitoring.

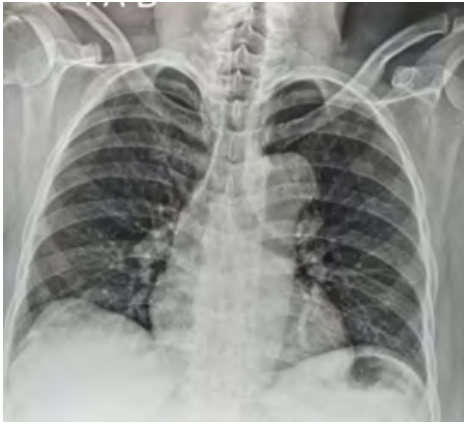

Figure 1: Radiographie du thorax de face Déroulement du bouton aortique

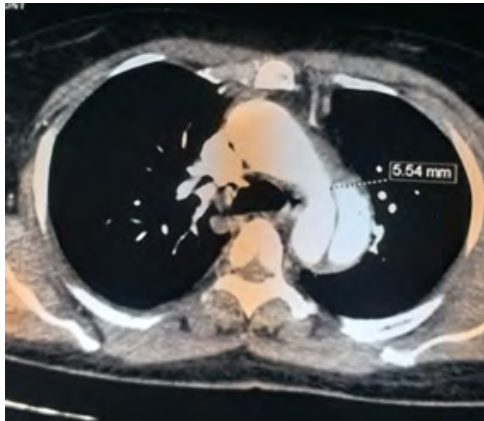

Figure 2: Angioscanner thoracique (Coupe transversale)
Solution de continuité d'environ 5.54 mm en regard de l'isthme de l'aorte

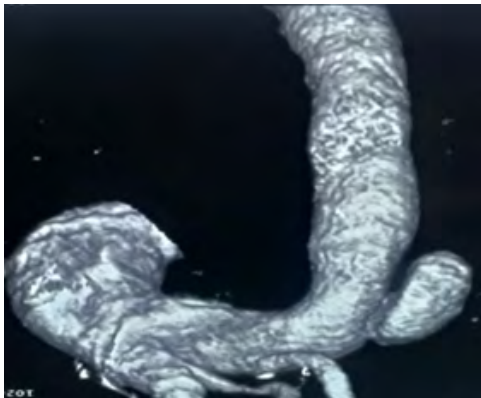

Figure 3: Angioscanner thoracique (Coupe longitudinale) Extravasation du produit de contraste




Figure 4: Angioscanner thoracique (Coupe longitudinale) Mise en évidence de la brèche

4. Discussion

Aortic lesions, called Traumatic Aortic Ruptures and more particularly of the aortic isthmus, are the most common vascular lesions in blunt chest trauma [4]. They account for 85% of aortic lesions secondary to blunt chest trauma [6].

The first case of aortic aneurysm following trauma was reported by Vesalius in 1557 [4].

In 90% of cases, deceleration is the main mechanism of isthmus lesions. It is fatal at the scene of the accident in 50 to 80% of cases and 8 to 10% die within six hours of the accident [1, 2, 6]. In 80% of cases, it is associated with other lesions [1, 2, 4, 6].

The rupture can involve the intima, or the intima and the media (subventricular rupture) or even the 3 tunics then causing cataclysmic internal bleeding and immediate death [1-4].

The clinical form most frequently encountered in patients who survive the initial trauma is sub-adventitial rupture or contained rupture, which may progress towards complete rupture or towards the progressive formation of a chronic post-traumatic aneurysm [1, 2, 5].

The lesions observed are divided into four grades of increasing severity [4] according to Parmley:

Grade 1: intimal tear; Grade 2: intramural hematoma; Grade 3: aortic pseudoaneurysm; Grade 4: total rupture.

In our case, the rupture was subventricular (Grade 3) and the evolution was favorable under medical treatment, with formation of aneurysmal thrombosis and disappearance of the intimal breach.

The diagnosis of isthmus rupture of the aorta should be systematically evoked, even without thoracic impact, in view of the violence of the trauma, the deceleration mechanism and the frequently associated polytrauma [1].

The clinical examination may inconsistently show a picture of pseudo coarctation: a reduction in femoral pulses, a mid-thoracic systolic murmur and anisotension and anisophygma between the upper and lower limbs [1].

This was not observed in our patient.

The chest X-ray taken on admission is more contributive with a sensitivity and specificity of 55 and 65% respectively [3]. The most important signs are those indicating the presence of hemo-mediastinum (positive predictive value of 15%) [3], in particular Enlargement of the superior mediastinum beyond 8 cm, loss of contours of the aortic button.

Other signs should be sought such as deviation of the trachea to the right; The lowering of the left main bronchus; deviation of an esophageal probe; left pleural fluid effusion; an apical pleural cap and associated parietal lesions (fractures of the sternum, first and second ribs, dorsal spine, clavicle with posterior displacement). In our case, the chest X-ray showed an unfolding of the aorta.

CT angiography should not be limited to examining the chest, but

should also look for associated lesions (head, spine, abdomen, etc.). It is a more sensitive examination than the chest X-ray. The diagnosis of Traumatic Aortic Rupture should be considered in the presence of a periaortic mediastinal hematoma, a pseudoaneurysm, an irregular aortic contour, a divided aortic lumen or an intimal flap [4]. The sensitivity of CT angiography is excellent (100% versus 92% for aortography), as is its specificity (83% versus 99% for aortography) [4, 6].

Transesophageal ultrasound (TEO) can be performed quickly, especially on a sedated patient in the intensive care unit or in the operating room. TEE is a very specific (95—100%) and insensitive (93%) examination [6].

In our case, the diagnosis was made by chest CT angiography.

On the therapeutic level, it has been shown that emergency surgery is not mandatory and that it can be postponed without increasing the risk of secondary rupture, subject to strict blood pressure control [1, 5]. Medical treatment is essentially based on beta-blockers to reduce kinetic energy and blood flow velocity as well as parietal tension (systolic stress) [5]. The treatment was based for a long time on open reconstructive surgery by prosthetic interposition. The first replacement of the descending aorta was performed by de Bakey and Cooley in 1953 [7]. The emergence and development of endovascular techniques have revolutionized the management of traumatic ruptures of the aortic isthmus, especially in emergencies and in the event of a lesion association involving the vital prognosis (head trauma, abdominal trauma). It is recognized to have several advantages over surgery, which is invasive and has high morbidity and mortality [2, 7]. In our case, the patient had received medical treatment.

5. Conclusion

Traumatic rupture of the aortic isthmus is a serious complication that can be life-threatening. Its diagnostic methods have benefited from the generalization of non-invasive explorations such as computed tomography and transesophageal echocardiography.

Surgical treatment can be delayed under cover of appropriate medical treatment (vasodilator and beta-blocker). [1]

The emergence and development of endovascular techniques have revolutionized its management [2].

References

1. Aïmar F, Lakehal R, Bouharagua R, Nezel R, Gueriti F, Bendjaballah S, et al. Traumatic rupture of the aortic isthmus: about three cases.
2. Boukerroucha R, Bendjaballah S, Messikh N, Aziza B, Ait-Moussa S, Badaoui HS, et al. Traumatic rupture of the aortic isthmus: about a case.
3. Lesèche G, Alsace JM, Castie Y. Acute post-traumatic rupture of the aortic isthmus.
4. Atchade E, Baumgarten R, Raux M. Traumatic lesions of the aortic isthmus.
5. Traumatic lesions of the aorta J.P. Goarin*, T. Barbry Department of anaesthesia-resuscitation, Pitié-Salpêtrière, 83, boulevard de l'Hôpital, 75651 Paris cedex 13, France
6. Denguir R, Frikha I, Kaouel K, Abdennadher M, Ziadi J, Jemel A, et al. Management of post-traumatic aortic isthmus ruptures. *J Mal Vasc.* 2013; 38(1): 13-21.
7. Taieb C, Hèla BJ, Abdessalem H, Majdi G, Hassen J, Aïman D, et al. Short-term and long-term results of covered endoprostheses for the treatment of aortic pathology: About 25 cases.