

A 25-Year-Old Female with Extensive Large Bowel Tumour: An Unexpected Finding from South East Asia

Qua CS^{1*}, Kannan S², Peh KB³ and Amar AHB⁴

¹Department of Gastroenterology, Mahkota Medical Centre, Malaysia

²Department of Radiology, Mahkota Medical Centre, Malaysia

³Department of Pathology, Mahkota Medical Centre, Malaysia

⁴Department of Surgery, Mahkota Medical Centre, Malaysia

*Corresponding author:

Choon-Seng Qua,
Department of Gastroenterology, Mahkota Medical
Centre, Malaysia

Received: 26 Feb 2024

Accepted: 06 Apr 2024

Published: 12 Apr 2024

J Short Name: JCFI

Copyright:

©2024 Qua CS, This is an open access article distributed under the terms of the Creative Commons Attribution License, which permits unrestricted use, distribution, and build upon your work non-commercially.

Citation:

Qua CS, A 25-Year-Old Female with Extensive Large Bowel Tumour: An Unexpected Finding from South East Asia. J Clin Med Img. 2024; V7(13): 1-2

1. Clinical Images

A 25-year-old female presented with a one-month history of right-sided abdominal pain, loss of appetite and weight loss. She had not had a bowel opening for the last 5 days.

Physical examination showed a thin (36.5kg) female with a palpable hard mass in the right iliac fossa. An abdominal and pelvic CT scan showed a large tumour involving the caecum, ascending colon up to the hepatic flexure (Figure 1), in addition to multiple mesenteric lymph nodes.

The distal terminal ileum was dilated. She had mild anaemia (Hb=9.2 g/dL) and normal serum CEA level. The provisional diagnosis at that time was colon cancer.

A colonoscopy with biopsy was initially planned but in view of the clinical findings indicating impending bowel obstruction, she proceeded directly to surgery after discussions with our colorectal surgeon.

Intraoperatively an extensive tumour was encountered involving the terminal ileum, caecum and ascending colon. A right hemicolectomy with aggressive local lymph nodes clearance were performed.

Her post-operative course was uneventful. During her follow up, the histopathology report of the resected specimen showed presence of multiple granulomas (Figure 2), along with presence of scanty acid-fast bacilli (AFB) (Figure 3).

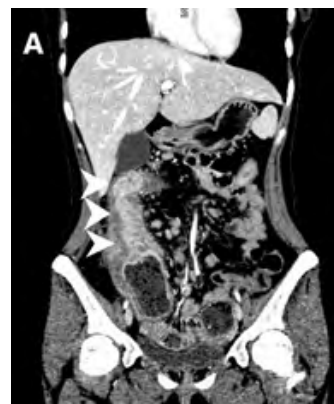

Figure 1

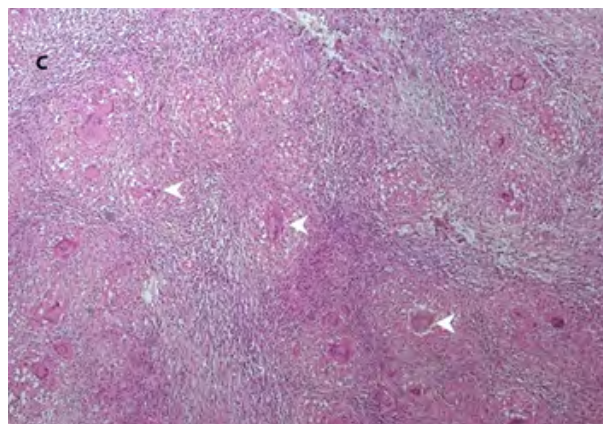


Figure 2

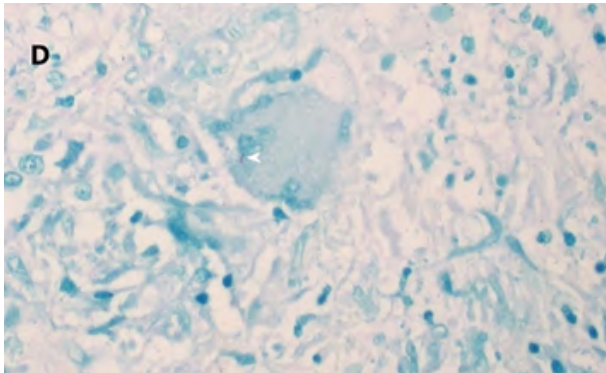


Figure 3

No malignant cell was detected. Her chest X-ray was normal. She was commenced on anti-tuberculous therapy and expected to make a complete recovery in one year.

Mycobacterium Tuberculosis (TB) is a versatile micro-organism capable of causing infections in many parts of the body, including the gastrointestinal tract [1]. This may occur either as a primary infection or concurrent pulmonary infection. It is a curable medical condition but sometimes surgery may be required due to its complications. In our country where TB is still endemic [2], such florid case is indeed rare, except amongst migrant workers.

References

1. World Health Organization. Global tuberculosis report 2013. Geneva: WHO. 2013.
2. Clinical practice guidelines: Management of tuberculosis (Fourth edition 2021), Ministry of Health, Malaysia. 2021.