

A BCC, You Can Find It Everywhere

Issoual K*, Achehboune K, Dahhouki S, Elloudi S, Baybay H and Mernissi FZ

Departement of Dermatology, Hassan II Hospital University, Fez, Morocco

Volume 3 Issue 1- 2020

Received Date: 21 Dec 2019

Accepted Date: 03 Jan 2020

Published Date: 08 Jan 2020

1. Abstract

BCC is by far the most frequent skin tumor, sun exposure is the most important risk factor in its pathogenesis, explaining its predominant localization on the head and neck. Its evolution is insidious, it is slowly progressive and painless, which often delays the diagnosis. We report a case of BCC on the trunk of fortuitous discovery.

2. Comment

72-year-old patient, without associated defects, who has a notion of sunbathing in the summer period who consults for rosacea for which he has been followed for years under treatment, During the clinical examination our intension was pulled by a lesion of the trunk, the patient does not remember the history of this lesion: he says he has had it for a few years, it sometimes bleeds, but asymptomatic.

On examination: it was about a small plaque of 1 cm, erythematous, oval well limited ulcerated in the center, with some crusts, raised and beaded edges, within many angioma cheery localize au niveau on dermoscopy: with an erythema background, telangiectasia and arborizing vessels, an blue-gray dots and small globule, Maple leaf like areas, Shiny white blotches and strands, and a central ulceration. The diagnosis was a BCC, it was confirmed histologically after a surgical excision.

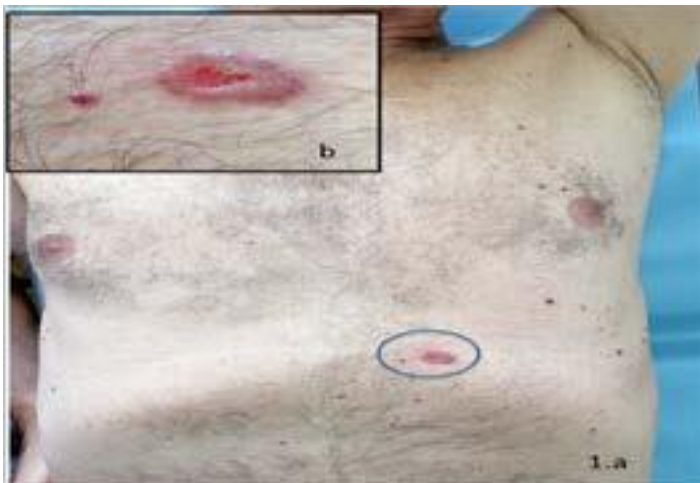


Figure 1 (a,b): erythematous plaque with a beaded edges and central ulceration of the trunk

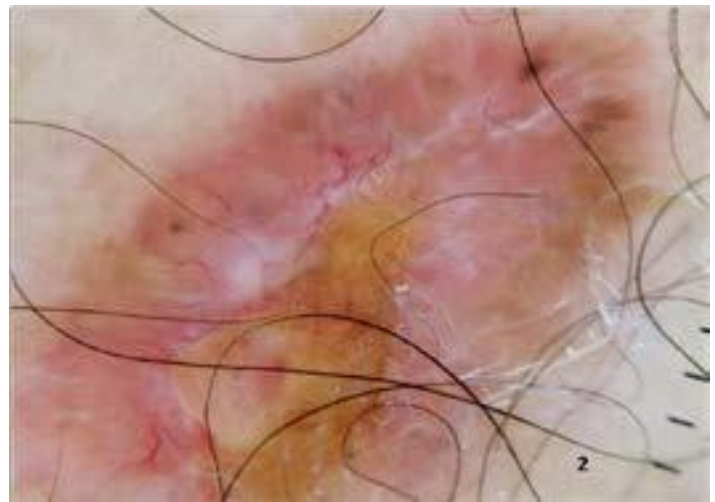


Figure 2: The dermoscopic photo shows: telangiectasia and arborizing vessels, a blue-gray dots and small globule, Maple leaf like areas, Shiny white blotches and strands, and a central ulceration.

*Corresponding Author (s): Khadija Issoual, Departement of Dermatology, Hassan II Hospital University, Fez, Morocco, Tel: 0212655085268, E-mail:khadijaissoual@gmail.com