

# Lymph Node Metastases Detected by PET-CT in Staging and Restaging Exams of Patients with Colon Adenocarcinoma: A Retrospective Study

Amorin C<sup>1</sup>, Dutra LD<sup>1</sup>, de Melo JIF<sup>1</sup>, Netto RORF<sup>2,\*</sup>, Fernandes VAR<sup>2</sup> and Mendonça MV<sup>1</sup>

<sup>1</sup>Department of Radiology and Diagnostic Imaging Center – CERDIL, Dourado/MS - Brazil

<sup>2</sup>Laboratory of Tissue Morphology, Faculty of Medicine of Jundiaí – FMJ, Jundiaí/SP - Brazil

Volume 4 Issue 8- 2020

Received Date: 28 May 2020

Accepted Date: 13 June 2020

Published Date: 18 June 2020

## 2. Key words

Positron Emission Tomography Computed Tomography; Colorectal Neoplasms; Diagnostic Imaging; Adenocarcinoma

## 1. Abstract

Imaging diagnosis and the identification of diseases and pathological processes is today, one of the most important tools of medicine. Sophisticated exams, such as PET-CT, enable the clinician to prescribe the best treatment for your patient, as well as a positive or more favorable prognosis for survival. In this retrospective study, the metabolic behavior, and the relationship of the size of lymph nodes near the sites affected by a colon and rectal cancer were verified. 28 tests were selected over two years, March 2015 to March 2017, of which patients had rectal or colon adenocarcinoma. Of these, 13 had an apparent glycolytic metabolism for glucose 18F-FDG, used in combination with computed tomography to locate tumors. Of these metabolically active tumors, 23.1% had a dimension of less than 1 cm, while 76.9% had lymph nodes with dimensions greater than 1 cm. The results of the F18-FDG glycolytic metabolism showed that metastatic lymph nodes larger than 1 cm presented a less predictable metabolic behavior, unlike lymph nodes smaller than 1 cm that the SUV remained between 2.5 to 4.0. It is concluded that these results can assist in the treatment of patients with colon and rectal cancers, in addition to helping the clinician to better understand the impact of different lymph node disorders in this region.

## 3. Introduction

Colon cancer includes tumors that affect one of the segments of the large intestine and the rectum, being one of the most common types of cancer in the world. It is estimated that there are approximately 30 thousand new cases per year, and of this surprising number, 14 thousand cause the death of patients [1]. Colon cancer is treatable and curable in most cases if detected early. Most of these tumors start from polyps, abnormal growth of the epithelial tissue that lines and constitutes the organ's mucosa. They can be benign or malignant lesions and the early identification of the appearance of these abnormal tissue formations is associated with a better patient prognosis [2]. However, late identifications can represent substantially low therapeutic efficacy. Since both the colons of the large intestine and the rectum are drained by veins that converge to the superior and inferior mesenteric veins, as well as to the internal iliac veins, respectively [3]. Therefore, in case of tumor metastases in these regions, the involvement of other locations, such as the lungs and the liver, may occur by means of the port-systemic anastomoses present in these regions, making treatment of the individual more difficult [1-3].

The symptoms presented by patients who have this disease are very

diffuse and easily confused with less severe diseases or may even go unnoticed by the patient[4]. Therefore, patients may experience changes in bowel habits, including diarrhea or constipation, as well as dark-colored pasty stools and the presence of blood in the stools. In addition, it is common for patients to complain of abdominal pain, colic, and gas. However, these symptoms, as previously described, may not represent a reason for the patient to seek medical help, therefore, more detailed examinations and which enable the more in-depth identification of the gastrointestinal tract and the organs that constitute it, are highly necessary [4-5].

Endoscopy and specific blood count allow the identification of occult blood in the stool, especially in patients belonging to the group at risk for this disease (people over 50 years old, mainly women with sedentary lifestyle habits). The World Health Organization, in its opinions and guidelines on this disease, indicates that systematic screening is essential in people over 50 years of age, in order to ensure that individuals who have this disease are treated at an early stage of development. However, once pro-oncogenic markers from such exams, endoscopy and blood count are identified, mapping the cancerous lesion is essential, as well as the proper location of the tumors along with the involved organs [1,3,4,6].

\*Corresponding Author (s): Raphael Oliveira Ramos Franco Netto, Laboratory of Tissue Morphology, Faculty of Medicine of Jundiaí – FMJ, Jundiaí/SP – Brazil, E-mail: raphael\_fri@hotmail.com

For this function, biopsy exams and histopathological analysis are the most performed, however, due to the variety of cancer subtypes that can develop in this region, as well as the rapid advances that can affect other parts of the body, faster and more sophisticated exams can help the clinical doctor in the diagnosis and quick start of treatment, as well as in the surgical intervention if necessary [1,2].

The pathogenesis of adenocarcinomas occurs sporadically, with 50% to 60% of cases being inherited, that is, caused by genetic factors. The main mutations that lead to the development of this type of colon and rectal cancer occur in the KRAS, NRAS and BRAF-V600E genes. In this sense, the mutations of the first two genes mentioned cause changes in the cellular behavior of the glandular epithelium and lymph nodes, a fact that should also be observed by the professional during his medical practice [5,7].

Thus, it is clear that the challenges imposed on medicine are numerous and growing, especially when analyzing the development of carcinogenic lesions. The methods used evolve as a whole, with an immense advance in diagnostic imaging methods. Among these techniques, PET-CT stands out, computed tomography by positron emission, a hybrid device, which aims to provide, in addition to the anatomical location of the lesions, through computed tomography, data related to the metabolism of the tumor, using PET, because it uses a glucose analogue, DG (deoxy glucose), marked with the radioisotope F-18 (fluorine eighteen), thus forming the radiopharmaceutical 18F-FDG (fluorodeoxyglucose)[8].

This glucose analogue is based on the principle that tumor cells, due to their high metabolism, consume more glucose, thus, they are then detected by radioactive glucose, a fact already demonstrated in many studies[9].

This method has been widely requested in the evaluation of numerous malignant neoplasms, both for staging, contributing to the planning of the initial treatment, as well as to the assessment of response to therapy[10].

Colon adenocarcinoma is a tumor that has its evaluation by PET-CT as a formal indication. The evaluation of lymph nodes has been the subject of many discussions in the literature, especially those smaller than 1.0 cm, where other radiological methods would have their sensitivity reduced. In many tomographic examinations, for example, these lymph nodes are not mentioned or are not given due importance [1]. The aim of this study is to demonstrate the existence and the metabolic characteristics of these lymph nodes, which can often be the only metastatic involvement of the patient, who can thus be submitted to rescue lymphadenectomy and progress to healing [1,10].

#### 4. Goal

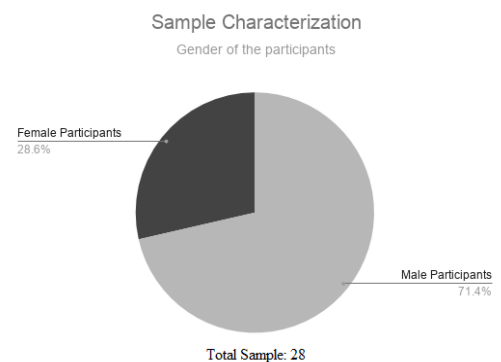
Identify associations between the size of lymph nodes found in the colon and rectum region and their average metabolic glucose consumption in PET-CT scans

sumption in PET-CT scans

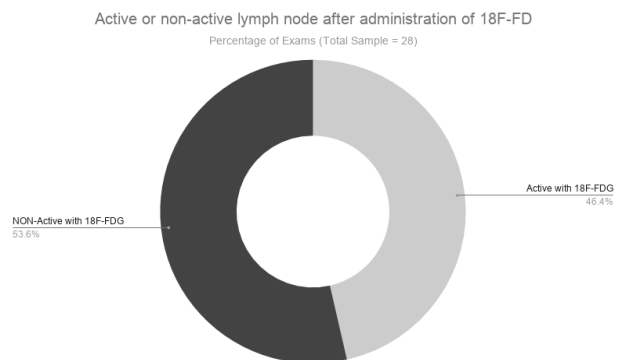
## 5. Material and Method

### 5.1. Sample Characterization

28 PET-CT exams were evaluated, from patients diagnosed with colon and rectum adenocarcinoma, from March 2015 to March 2017, with the following data being determined: lymph node size and degree of glucose metabolism administered in the exam (radiopharmaceutical 18F-FDG (fluorodeoxyglucose). The inclusion criteria used were PET / CT scans in which the diagnosis of colon adenocarcinoma was confirmed, within the period described. As well as colon cancer diagnoses in which they were not excluded. treated adenocarcinomas.



**Figure 1:** Characterization of the study sample. Values observed as a percentage of the total number of exams (n = 28) observed over the time period (March 2015 to March 2017).



**Figure 2:** lymph nodes that are metabolically active or not, when using 18F-FDG.

### 5.2. Experimental Design

A retrospective study of PET / CT exams performed at a private clinic in Dourados, state of Mato Grosso do Sul, Brazil. The PET-CT device used was the GE-Discovery 710, serial number PET-13330 PTC. The average waiting/resting time between the injection and the acquisition of the images of each patient varied between 50 and 60 minutes.

The acquisition of Computed Tomography was performed first using the following parameters: tube voltage: 120 kV, tube current, automatic CT exposure control, 1.375 pitch factor, table rotation, 27.5 mm s<sup>-1</sup> and cut thickness 3.75 mm.

The acquisition of PET was made later and performed in three-dimensional mode with scanning the skull to the root of the thighs. The acquisition time varied between 2-5 min/bed and the total acquisition of images varied between 18 and 22 minutes.

The injected dose was calculated by the patient's weight, taking into account 0.12-0.14 mCi / kg and varied between 8 to 10 mCi. All patients underwent the preparation with restriction to sugars and carbohydrates, physical exercises, and exposure to cold 24 hours before the exam, fasting for 4 hours and maintaining adequate blood glucose levels. Patients were instructed to urinate before scanning to reduce bladder buildup. PET-CT exams were selected between March 2015 and March 2017, in which patients had colon cancer, adenocarcinoma subtype. The analysis of the lymph nodes found was made, evaluating the degree of glucose metabolism and its sizes.

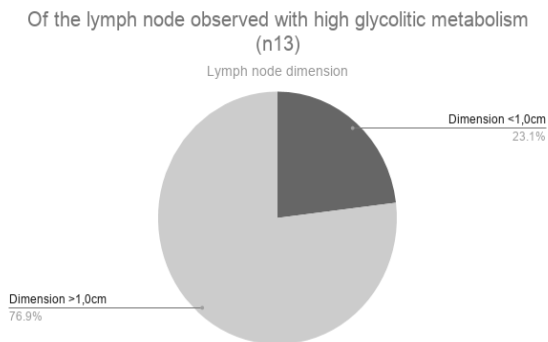


Figure 3: metabolically active lymph nodes and their dimensions.

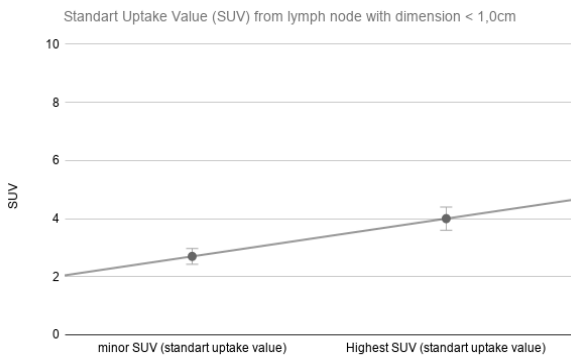


Figure 4: Variation of the metabolic rate observed in lymph nodes smaller than 1 cm

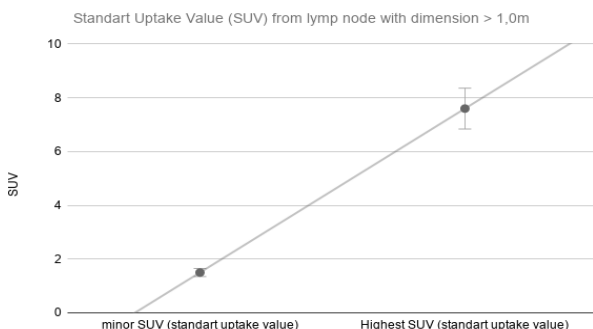


Figure 5: Variation in the metabolic rate of glucose from lymph nodes greater than 1 cm

### 5.3. Statistical Analysis

The statistical analysis employed in the study was descriptive and comparative between metabolic activity and the size of the tumor observed.

### 6. Results

Initially, the characterization of the sample of this study will be presented. The results are expressed in graphs for easy viewing. Graph 1 shows the results of the number of exams in which they were selected along with the time cut. 28 tests were evaluated, of which 13 were with metabolically active lymph nodes for 18F-FDG (fluorodeoxyglucose) and 15 were not.

Of the percentage of metabolically overactive lymph nodes, that is, that had a metabolic index for the glucose used in this test before the PET-CT exam, the number was equal to 13, representing 46.4% of the total sample. Of these 13 metabolically active, 23.1% had dimensions reduced to less than 1cm and 76.9% with dimensions greater than 1cm, data presented in graph 2 and 3.

Lymph nodes that had dimensions smaller than 1 cm had a variation in the metabolic rate of glucose 18F-FDG between 2.5 to 4.0 SUV. Fact that can be seen in Graph 4.

In turn, the variations in metabolic rates of glucose 18F-FD used in PET-CT scans in lymph nodes larger than 1 cm were from 1.5 to 7.0 SUV. Aspect that can be seen in graph 5.

### 7. Discussion

The results of this study indicated a possibility of a correlation between the size of a lymph node and the metastatic potential of cervical or recurrent cancer, a fact that corroborates the existing literature and shows recent results in other types of cancer [1,2,9]. The novelty is attributed to a etiology of analyzed cancer, of the lower limits of the gastrointestinal tract. Of the 28 exams, 13 found active metabolized lymph nodes, a fact that should be understood as of great importance in clinical diagnosis during diagnosis, an increase in glucose consumption may occur F18-FDG indicates the possibility of cell replication in the organ in a way that would be little needed or without an adequate selection of the cell cycle phases, without new tumours [1]. Associated with this, with a high rate of SUV that receives the lymph nodes in general, that is, above 2.5, it indicates that these metabolisms are also metabolized and also have a high correlation with metastasis to the affected common organs (lungs, kidneys, bones and liver).

These findings, which corroborate with literature and help in the design of new studies, finally, few scientific records analyze this exam (PET-CT) associated with the progress of cancer and lymphatic effects caused by the involvement of a recently published study [8]. However, another particularly important aspect observed in this study was the correlation between the size of the lymph node and its metabolism before the PET-CT exam. According to

the results presented in graphs 4 and 5, the size of the lymph node seems to present an atypical behavior regarding the glycolytic metabolism of this type. When analyzing graph 4, which indicates the glycolytic metabolic behavior of lymph nodes smaller than 1 cm, it appears that the variation of 2.5 to 4 SUV does not metabolize glycolytic indicates a linear function equivalent to  $1.3X + 2.7$ , while the SUV variation in lymph nodes with dimensions greater than 1 cm, shown in graph 5, showed an SUV variable of 1.5 to 7.0, establishing a linear function equivalent to  $6.1X + 1.5$ .

This information must be understood very carefully, due to the low number of applications used after two years, that this retrospective research is carried out, as well as the implications that these results can take. In this way, it is possible to mortgage which lymph nodes smaller than 1 cm have a less intense metabolic behavior and within an average expectation of 3.25 SUVs with changes between 2.5 and 4.0 SUVs. However, lymph nodes with cancer metastases of resumption and colon, in specific adenocarcinomas, with dimensions larger than 1 cm, as the metabolic restrictions are more unpredictable.

The similar result was found in the study by Sürücü and colleagues in which they were observed by the same test used in the testing of tumor malignancy results from lymph node involvement. The authors did not observe differences between the number of mitoses and the depth of the lymph node, however, or the study of these researchers was carried out in the oral cavity.

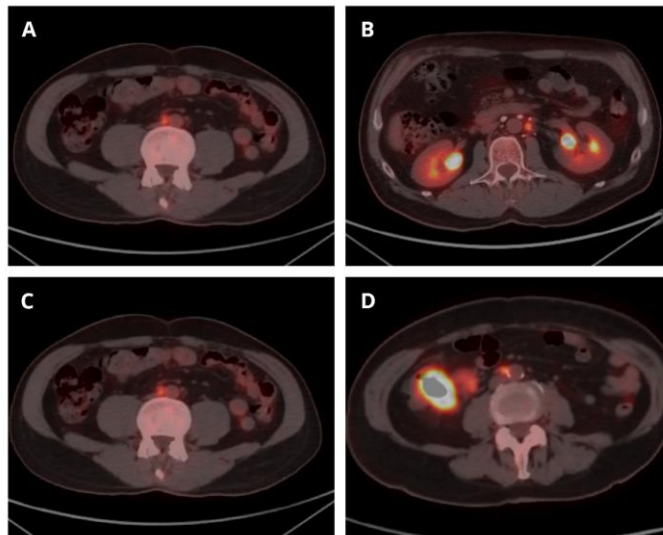
Because of the observed results and the representative knowledge gap, which has respect for the metabolic behavior of rectal lymph nodes affected by metastases or this study, it is possible to select new changes after correlation between the size of the lymph node and its metabolic behavior.

Since, previously, measurements of these lymph nodes were given more value, we can observe with PET-CT that lymph nodes with smaller sizes may be colon adenocarcinoma is a common disease and can be lethal. Approximately 25% of patients metastasize at the initial diagnosis and 50% will present throughout the follow-up. The most frequent sites of metastases are lymph nodes, liver, lungs, and bones.

The PET-CT exam provides both anatomical and functional information, through glycolytic metabolism. The lymph node evaluation of this type of tumor using PET-CT incorporated one more valuable data for staging and restaging, which was the metabolic evaluation affected by the tumor and that should have their importance recognized.

With the analysis of this study, it can be seen that 10% of the selected patients had lymph node metastases smaller than 1.0 cm. Such lymph nodes, if evaluated only with screening by Computed Tomography, would not possibly be considered pathological. As a result, patients would only undergo surgical resection of the tumor,

not undergoing adjuvant chemotherapy, which could cause a drop in their overall survival.



**Figure 6:** Lymph nodes observed in PET-CT examination, using glucose F18-FD to identify the SUV. Table A indicates a lymph node with a dimension of 0.9 cm and SUV of 3.7. Table B presents a lymph node with a dimension of 0.8 cm and an SUV of 3.1. Table C indicates a 0.7 cm lymph node and a 4.0 SUV. Table D indicates a 0.9 cm lymph node with a 2.7 SUV.

## 8. Conclusion

Lymph node evaluation with PET-CT in colon adenocarcinomas was extremely important since it is possible to observe changes in the treatment and survival of patients and a better understanding of the metabolism of tumors.

## References

1. Sürücü E, Polack BD, Demir Y, Durmusoglu M, Ekmekçi S, et al. Dual-phase F-18 FDG PET-CT in staging and lymphoscintigraphy for detection of sentinel lymph nodes in oral cavity cancers. *Clin Imaging*. 2015; 39(5): 781-6.
2. Herbertson R A, Lee ST, Tebbutt N. AM Scott. The expanding role of PET technology in the management of patients with colorectal cancer. *Annals of Oncology*. 2007; 18: 1774–1781.
3. Sergio Bertoglio, Sergio Sandrucci, Pierluigi Percivale, Matteo Goss, Marco Gipponi, Luciano Moresco, Baudolino Mussa, Antonio Mussa. Prognostic value of sentinel lymph node biopsy in the pathologic staging of colorectal cancer patients. *J Surg Oncol*. 2004; 85(3): p.166-170.
4. Bilchik AJ. Ultrastaging of early colon cancer using lymphatic mapping and molecular analysis. *Eur J Cancer*. 2002; 38(7): 977-985.
5. Bilchik AJ, Trocha SD. Lymphatic mapping and sentinel node analysis to optimize laparoscopic resection and staging of colorectal cancer: an update. *Cancer Control* 2003; 10(3):219-222.
6. Vriens D, de Geus-Oei LF, van der Graaf WT. Tailoring therapy in colorectal cancer by PET-CT. *Q J Nucl Med Mol Imaging*. 2009; 53(2): 224-44.
7. Wiering B, Krabbe PF, Jager GJ, Oyen WJ, Ruers TJ. The impact of

- fluor-18-deoxyglucose-positron emission tomography in the management of colorectal liver metastases. *Cancer* 2005; 104(12): 2658-70.
8. Talbot JN, Paycha F, Balogova S. Diagnosis of bone metastasis: recent comparative studies of imaging modalities. *Q J Nucl Med Mol Imaging*. 2011; 55: 374-410.
  9. Utler DI, Wong RJ, Schoder H, Kraus DH. The current status of positron-emission tomography scanning in the evaluation and follow-up of patients with head and neck cancer. *Curr Opin Otolaryngol Head Neck Surg*. 2006; 14: 73-81.
  10. Yusuf Demir, Berna D Polack, Canan Karaman, Ozhan Ozdoğan, Erdem Sürücü, Sadet Ayhan, Atila Akkoçlu, Nezh Ozdemir. The diagnostic role of dual-phase (18)F-FDG PET/CT in the characterization of solitary pulmonary nodules. *Nucl Med Commun*. 2014; 35: 260-267.
  11. Kitagawa Y, Sano K, Nishizawa S, Nakamura M, Ogasawara T, Sadaoto N, et al. FDG-PET for prediction of tumour aggressiveness and response to intra-arterial chemotherapy and radiotherapy in head and neck cancer. *Eur J Nucl Med Mol Imaging*. 2003; 30: 63-71.