

The Panda Sign

Jivanjee M*

Junior Doctor, North West Hospitals NHS Trust, London

Volume 3 Issue 3- 2020

Received Date: 24 Jan 2020

Accepted Date: 03 Feb 2020

Published Date: 08 Feb 2020

Clinical Image

A 39 year old right handed lady presented with a 3 month history of worsening chin and bilateral leg tremors. Secondary to this she had multiple falls. This was on a background of 18 months of intentional hand tremors. On examination she had marked rigidity bilaterally, intention tremor and an unsteady gait. Kayser-Fleischer rings were noted on examination of her eyes.

An MRI brain (Figure 1) was performed which demonstrates the 'Panda sign' in the midbrain from axial T2-weighted imaging. There is normal intensity of the red nuclei (forming the eyes) and lateral portion of pars reticulata of the substantia nigra (forming the ears), within hyperintensity of the tegmentum. Hypointensity of the superior colliculus (forming the chin) is also seen.

A diagnosis of Wilson's disease was made.

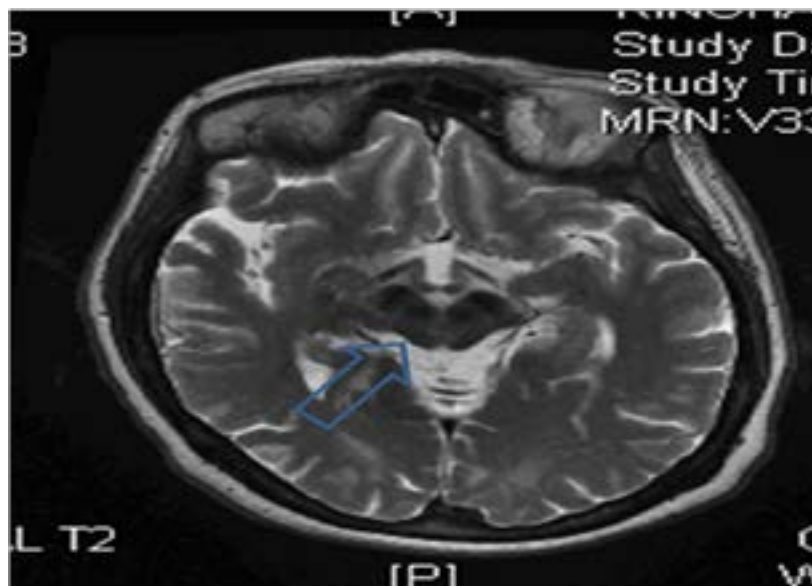


Figure 1

*Corresponding Author (s): Mufaddal Jivanjee, Junior doctor, North West Hospitals NHS Trust, London, E-mail: mufaddal.jivanjee@nhs.net

Citation: Jivanjee M, Junior Doctor, North West Hospitals NHS Trust, London. Journal of Clinical and Medical Images. 2020; V3(3): 1-1.