

# Intrathoracic Splenosis Detected by $^{68}\text{Ga}$ -DOTATOC PET/CT and Examined by Multimodal Imaging

Leporace M, Calabria F\*, Tavolaro R and Bagnato A

Department of Nuclear Medicine and Theranostics, "Mariano Santo" Hospital, 87100, Cosenza, Italy

Volume 4 Issue 8- 2020

Received Date: 29 May 2020

Accepted Date: 14 June 2020

Published Date: 18 June 2020

## 2. Key words

$^{18}\text{F}$ -FDG PET/CT;  $^{68}\text{Ga}$ -DOTATOC; splenosis; MRI; CT.

## 1. Abstract

We examined a patient with  $^{68}\text{Ga}$ -DOTATOC PET/CT, during follow-up of lung neuroendocrine tumor; patient anamnesis was also positive for post-traumatic splenectomy. Intense uptake was observed in splenosis of the splenic loggia and in a mediastinal node: this last finding was suspicious for metastasis of neuroendocrine tumor.  $^{18}\text{F}$ -FDG PET/CT showed low tracer uptake in both mediastinal lymph node and abdominal splenosis. Contrast enhanced CT allowed to correctly identify mediastinal lymph node as a further localization of splenosis due to the

intrathoracic herniation of the stomach. MRI, performed at follow-up, confirmed the diagnosis. Multimodal imaging can help in reaching diagnosis, avoiding invasive diagnostic procedures.

A 64-year-old woman was referred to our Department, 6 months after exeresis of lung neuroendocrine tumor (NET). Patient also undergone, 12 years before, post-traumatic splenectomy.

PET/CT demonstrated high  $^{68}\text{Ga}$ -DOTATOC (*a*, curved arrows) and mild  $^{18}\text{F}$ -FDG uptake (*b*) in the lower mediastinum and in the splenic loggia. The mediastinal focus of high  $^{68}\text{Ga}$ -DOTATOC and mild  $^{18}\text{F}$ -FDG uptake was associated with hypodense node, suspicious for NET metastasis, showed in axial  $^{68}\text{Ga}$ -DOTATOC (*c*) and  $^{18}\text{F}$ -FDG (*d*) PET/CT views. Nodes in splenic loggia were considered splenosis.

Subsequently, contrast-enhanced CT demonstrated heterogeneous enhancement in a 2.2 cm wide mediastinal node of intrathoracic splenosis (*e*) due to gastric supra-diaphragmatic herniation as well as further nodes of splenosis in the the splenic loggia.

Three months after, MRI showed unchanged the mediastinal node (*f*), allowing better discrimination from gastric wall, confirming the diagnosis of intrathoracic splenosis.

Following splenic injury, splenosis can be due to heterotopic auto-transplantation of splenic tissue [1]. Abdominal splenosis, avid of  $^{68}\text{Ga}$ -DOTATOC [2] and  $^{18}\text{F}$ -FDG [3] (*g*, *h*) and mimicking malignant tumor, is already described. Similarly, is known the uptake of somatostatin analogue tracer in intrathoracic splenosis at *Single Photon Emission Computed Tomography* [4].

In some cases, as in our patient,  $^{68}\text{Ga}$ -DOTATOC avid intrathoracic splenosis can be misdiagnosed as NET metastasis. For the best of our knowledge, this is not reported in literature.

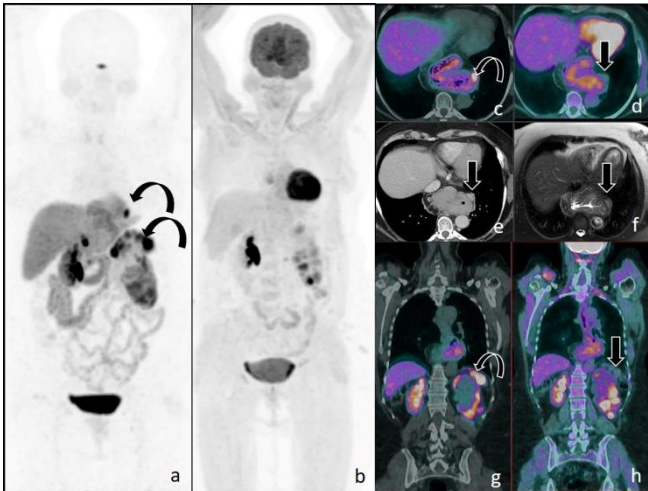
Therefore, nuclear physicians cannot exclude the possibility of intrathoracic splenosis as diagnostic pitfall of somatostatin analogues tracers. Anamnesis and multimodal imaging [5] can support diagnosis, avoiding further invasive procedures.

Mario Leporace (MD) examined CT and MRI patients scan; Ferdinando Calabria (MD) designed and wrote the paper; Rosanna Tavolaro (MD) examined  $^{68}\text{Ga}$ -DOTATOC scan and made bibliographic research; Antonio Bagnato (MD) examined  $^{18}\text{F}$ -FDG scan and critically revised the manuscript.

\*Corresponding Author (s): Ferdinando Calabria, Department of Nuclear Medicine and Theranostics, "Mariano Santo" Hospital, 87100, Cosenza, Italy. Tel: +39 3283337036, E-mail: ferdinandocalabria@hotmail.it

Citation: Calabria F et al., Intrathoracic Splenosis Detected by  $^{68}\text{Ga}$ -DOTATOC PET/CT and Examined by Multimodal Imaging. Journal of Clinical and Medical Images. 2020; V4(8): 1-2.

## Figures



## References

1. Ksiadzyna D, Pena AS. Abdominal splenosis. *Rev Esp Enferm Dig.* 2011; 103: 421-426.
2. Treglia G, Giovanella L, Muoio B, Caldarella C. Splenosis Mimicking Relapse of a Neuroendocrine Tumor at Gallium-68-DOTATOC PET/CT. *Nucl Med Mol Imaging.* 2014; 48: 163-165.
3. Martínez Lorca A, Coronado Poggio M, Hernández Pérez I, Ramírez Escalante Y, Rizkallal Monzon S, Marín Ferrer MD. [Utility of ( $^{99m}\text{Tc}$ ) Tc-labelled heat-denatured erythrocyte scintigraphy and  $^{18}\text{F}$ -FDG PET-CT to differentiate accessory spleens from tumoral metastases. A case report]. *Rev Esp Med Nucl Imagen Mol.* 2015; 34: 68-69.
4. Mahmoudian B, Javadrashid R, Fakhrajoo A. Intrathoracic splenosis: a rare false-positive cause of somatostatin imaging in characterization of solitary pulmonary nodule. *Clin Nucl Med.* 2015; 40: 138-140.
5. Calabria FF, Chiaravalloti A, Jaffrain-Rea ML, Zinzi M, Sannino P, Minniti G, et al.  $^{18}\text{F}$ -DOPA PET/CT Physiological Distribution and Pitfalls: Experience in 215 Patients. *Clin Nucl Med.* 2016; 41: 753-60.