

## Conservative Treatment Post-Op Tension Pneumocephalus Following Fess: A Case Report

Tareq AS, Ibraheem S, Alhasan S and Mudhaffer T

Amman Hospital, India

### \*Corresponding author:

Abu Saade Tareq,  
Amman Hospital, India

Received: 01 July 2024

Accepted: 10 July 2024

Published: 15 July 2024

J Short Name: JCMi

### Copyright:

©2024 Tareq AS, This is an open access article distributed under the terms of the Creative Commons Attribution License, which permits unrestricted use, distribution, and build upon your work non-commercially.

### Keywords:

Tension pneumocephalus; post-operative complication; FESS post-operative complications; ENT; Neurosurgery; Conservative treatment; Sinus endoscopy

### Citation:

Tareq AS, Conservative Treatment Post-Op Tension Pneumocephalus Following Fess: A Case Report. J Clin Med Img. 2024; V7(20): 1-5

## 1. Abstract

Tension pneumocephalus, though rare, poses a significant risk following neurosurgical procedures, involving the buildup of pressurized air within the cranial cavity. Here, we present the case of a 13-year-old male who experienced a right nasal septal deviation after trauma, subsequently developing symptoms indicative of increased intracranial pressure due to tension pneumocephalus. Swift identification and urgent surgical intervention resulted in successful decompression and symptom resolution. This case highlights the critical importance of promptly recognizing early signs of tension pneumocephalus in post-neurosurgical patients and the necessity for immediate management to avert adverse outcomes.

## 2. Introduction

Tension pneumocephalus, although rare, represents a significant complication post-neurosurgical procedures, marked by the pressurized accumulation of air within the cranial cavity. Typically arising from dural defects or leaks in cerebrospinal fluid, it allows air entry into the cranial vault, where it becomes trapped, exerting pressure on brain structures and elevating intracranial pressure. Despite its infrequency, tension pneumocephalus can yield severe consequences if not promptly identified and treated. Herein, we present a case of tension pneumocephalus subsequent to right nasal septal deviation, emphasizing its clinical manifestation, diagnostic assessment, and management of this uncommon yet critical complication.

## 3. Case Presentation

A 13-year-old male patient, presented to the ER department complaining of severe headache that is not improving with analgesics and it improves while seated and gets worse when supine. The patient had undergone FESS (functional endoscopic sinus surgery) 2 days before his presentation to our hospital. On clinical examination, the patient had shallow breathing due to his severe headache, irregular irregular heart rhythm, and follicular tonsils. The neurological examination was normal. Blood work was done which included a CBC, CRP, Mg, Ca and serum electrolytes; the patient had leukocytosis and mildly elevated CRP. ECG was done and showed multiple PVC and irregular irregular bradycardia. A brain CT scan was done. The report concluded mount fuji sign, suggestive of tension pneumocephalus, and a suspected defect in the roof of right ethmoidal air cells away from crista galli around 2.5 cm anterior to it. Along with another bony defect noted at the left side away from crista galli around 2.5 cm anterior to it.

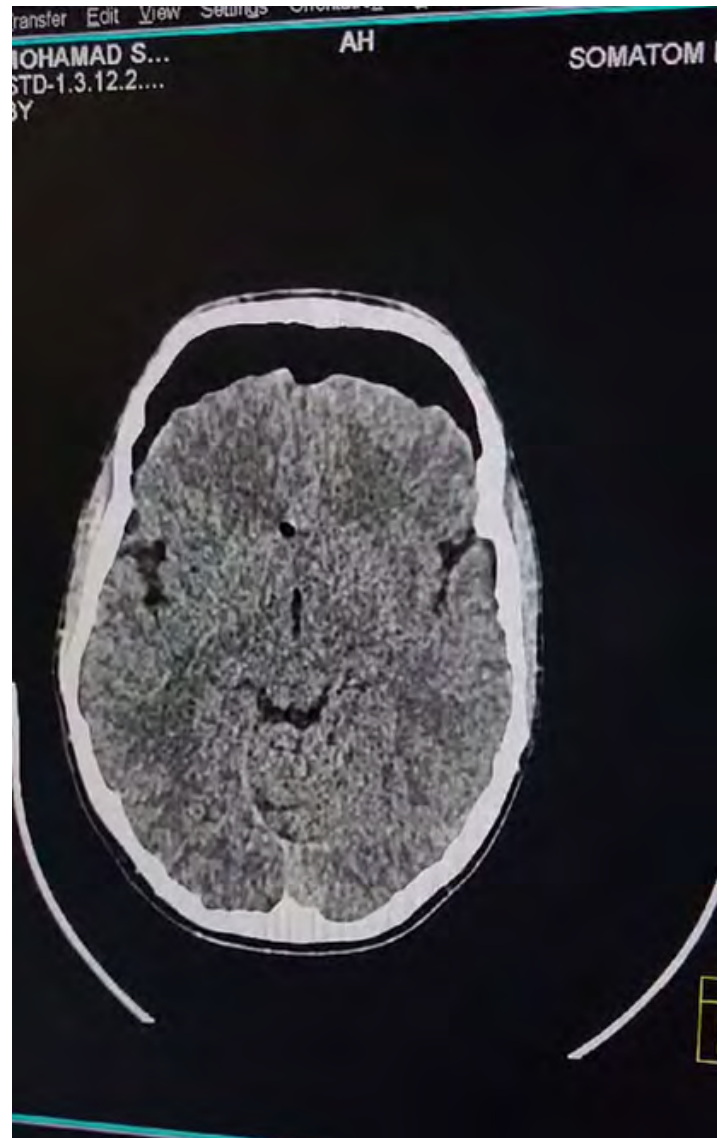
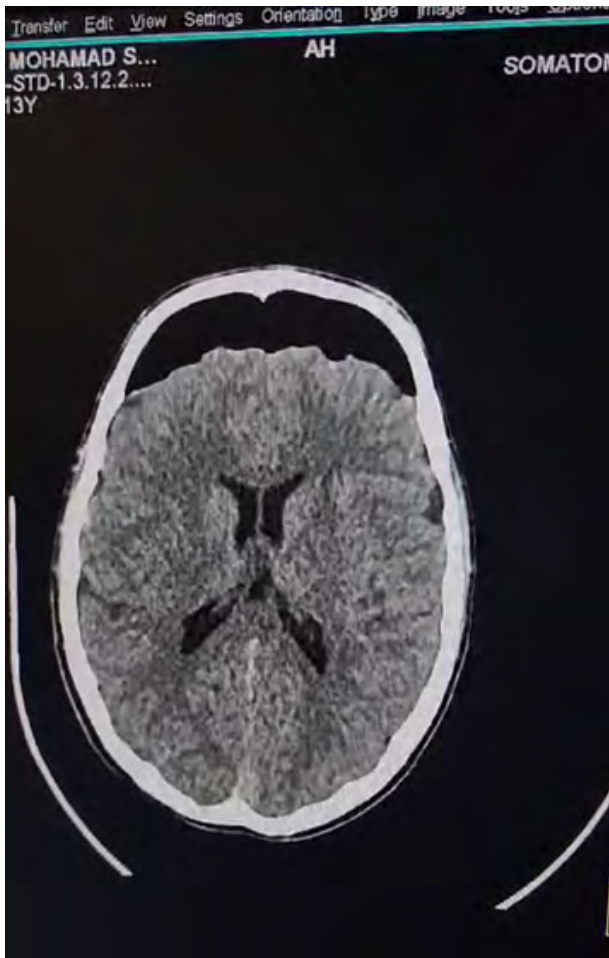
Surgical History: Neonatal Craniotomy

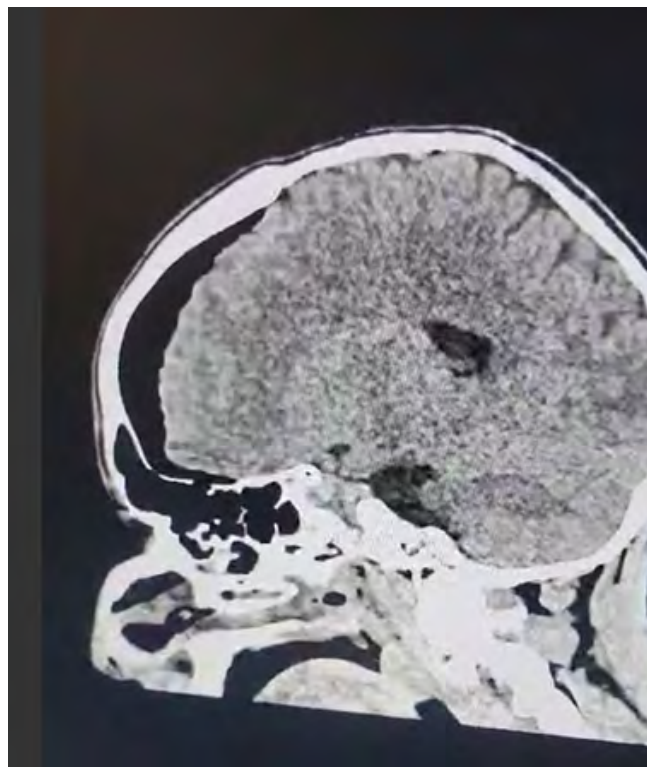
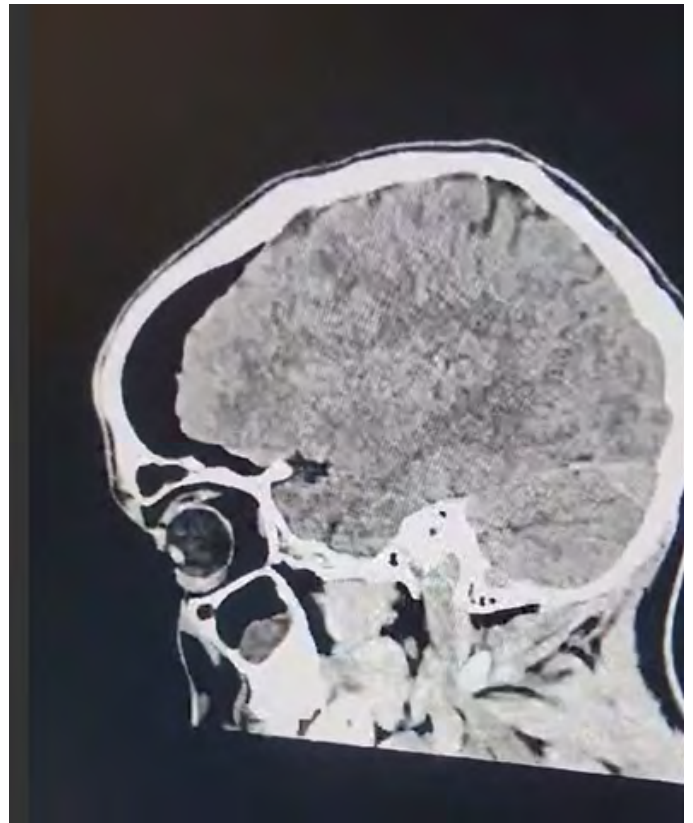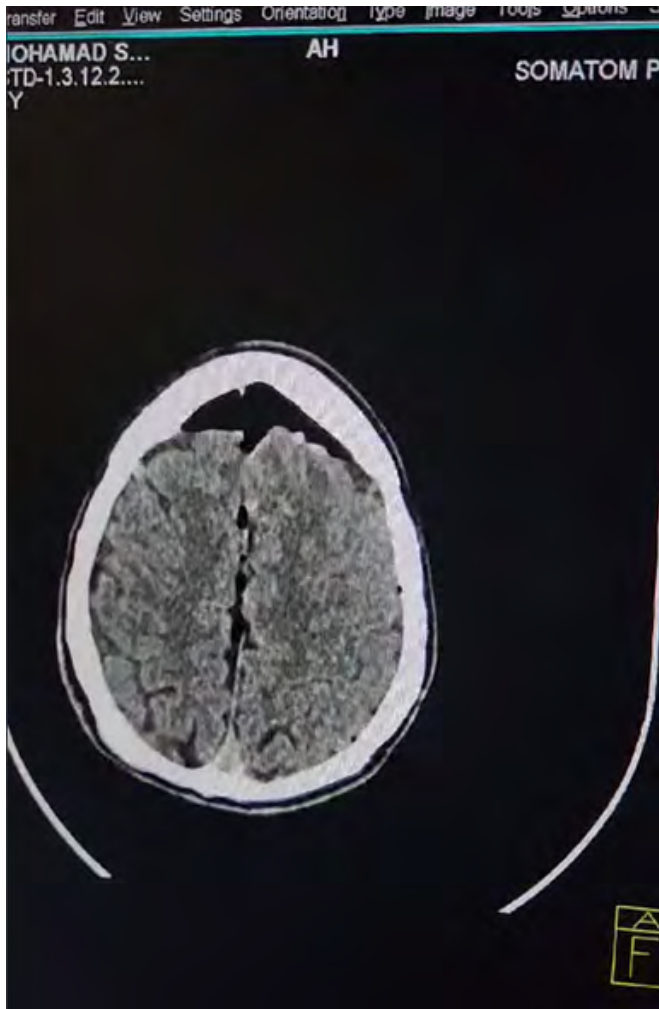
Medical History: Free

Drug History: Free

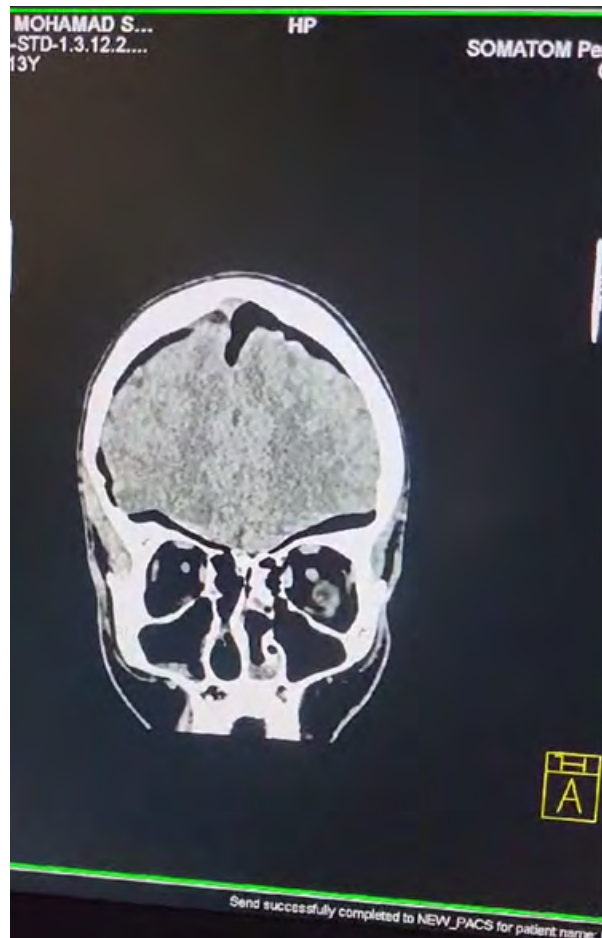
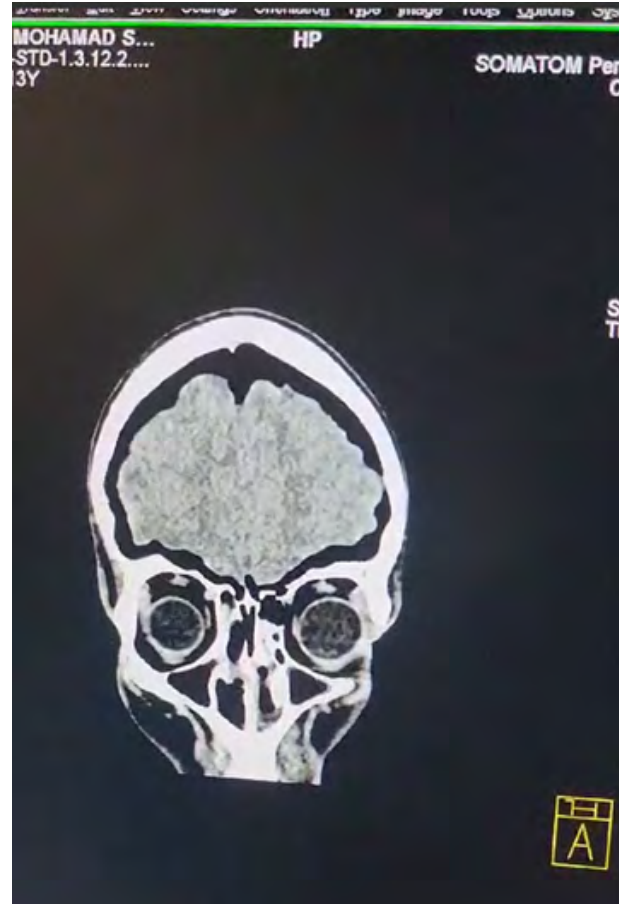
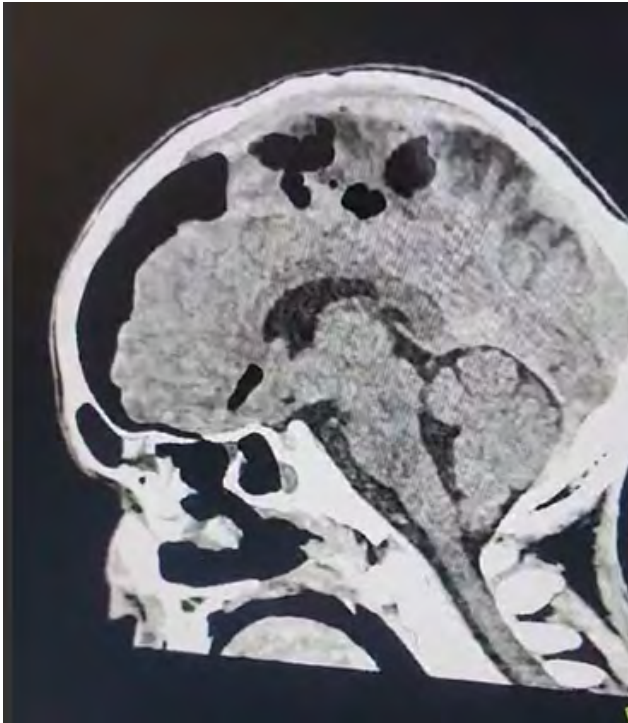
Vitals: Blood Pressure: 125/70; Temperature: 36.9

BPM:49; RR:19; SPO2:95









#### 4. Discussion

A 13-year-old male patient underwent FESS operation on the 7<sup>th</sup> of march, 2024. After the operation, the patient was complaining of mild Headache that was ignored thinking it was normal post op complain. Therefore, he was discharged on the next day. The following day, the 9<sup>th</sup> of March 2024, the patient returned to the hospital to the ER department complaining of severe headache of 2 days duration post FESS operation, on physical exam the patient found to be with irregular irregular rhythm with no further manifestation on neurological exam was noted. Other than the heart rate (49 BPM), vitally the patient was stable. BRAIN CT was ordered accordingly showing gas density in Both frontal and parietal lobes, Mount Fuji sign suggesting Pneumocephalus. Moreover, this incident happened post op as mentioned before after a defect seen in the roof of the right ethmoidal air cells and on the left side of the anterior to the crest gala. The pneumocephalus had a maximum AP diameter of 2.00 cm. The patient was admitted to the surgical ward and was started on meningococcal dose of ceftriaxone 2g IV BID, and vancomycin 1g IV BID. Moreover, a non-breather mask was placed, and the patient was covered by analgesics PRN. Also, He was placed on Dexamethasone 8mg BID IV, and the bed angle was kept at an angle of 30 degrees. Vital signs were monitored hourly. Both Neurosurgery and cardiology consultations were requested. Phenytoin 100mg TID was started as a prophylactic to seizures that might happen due to the tension pneumocephalus per neurosurgery order. The cardiology consultant concluded that there is no relation between arrhythmia and tension pneumocephalus. Five days after the admission of the patient, a follow-up Brain CT-scan was made, and it concluded that the pneumocephalus AP diameter has been reduced to 1.4 cm. Hence, the patient was discharged

home and was instructed not to breathe via his nose, rather, via his mouth. Furthermore, the patient's parents purchased a home oxygen machine to keep the patient on a non-rebreather mask along with analgesic tabs. On the 30<sup>th</sup> of march, 2024 and 24<sup>th</sup> of April 2024, the patient returned to the hospital, to the radiology department to do brain CT to follow up his case. Both CT showed no evidence of focal brain lesions or intracranial hemorrhage along with normal ventricular system and cisterns with no mass effect or midline shifting.

#### 5. Conclusion

post-op tension pneumocephalus is a serious condition that needs prompt intervention, Thus, complaints such as Headaches post sinus endoscopic operations should be taken seriously, as it can suggest and ultimately lead to life-threatening complications. Ergo, early recognition through imaging techniques, in particular, CT scans are vital for accurate early recognition. The treatment for mentally/vitally stable patients include conservative treatment should be taken into consideration. However, if the patient had no improvements, or is vitally/mentally unstable, surgical intervention is crucial to minimize the outcomes of tension pneumocephalus.

#### 6. Acknowledgements

We extend our gratitude to the patient and their family for their collaboration and permission for the publication of this case report. We would also like to thank Dr. Awny Musharbesh, and Dr. Imad Khresat, for their expertise and their guidance to the treatment of this case. Also, we would like to thank Dr. Ibraheem Shoubash, and Dr. Sadeq Al-Karmi for their help in facilitating this study.