

Acute Coronary Syndrome in HIV Patients: The Role of Immune System in Cardiovascular Disease and its Red Flags in Cardiovascular Imaging

Monaco ML¹, Tocci G², Bertella E¹, Cremonesi A¹, Volpe M³ and Barbato E³

¹Cardio Center, Humanitas Gavazzeni, Bergamo, Italy

²Hypertension Unit, Division of Cardiology, Department of Clinical and Molecular Medicine, Faculty of Medicine and Psychology, University of Rome Sapienza, Sant'Andrea Hospital, Rome, Italy; IRCCS Neuromed, Pozzilli, IS, Italy

³Cardiology Unit, Department of Clinical and Molecular Medicine, Sant'Andrea Hospital, Sapienza University of Rome, Rome, Italy

*Corresponding author:

Maria Lo Monaco,
Cardio Center, Humanitas
Gavazzeni, Bergamo, Italy

Received: 18 Sep 2023

Accepted: 24 Oct 2023

Published: 30 Oct 2023

J Short Name: JCMi

Copyright:

©2023 Monaco ML, This is an open access article distributed under the terms of the Creative Commons Attribution License, which permits unrestricted use, distribution, and build upon your work non-commercially.

Citation:

Monaco ML, Acute Coronary Syndrome in HIV Patients: The Role of Immune System in Cardiovascular Disease and its Red Flags in Cardiovascular Imaging. J Clin Med Img. 2023; V7(5): 1-4

Keywords:

Human immunodeficiency virus; Antiretroviral therapy; Acute coronary syndromes; Late microvascular obstruction; Cardiovascular prevention

1. Background

Widespread use of contemporary antiretroviral therapy (HAART) globally has transformed HIV disease into a chronic illness associated with excess risk for disorders of the heart and circulatory system. The global burden of human immunodeficiency virus-1 (HIV)-associated cardiovascular (CV) disease has tripled over the past two decades and is now responsible for about 2.6 million DALYs per annum with the greatest impact in sub-Saharan Africa and the Asia Pacific regions [1].

Current clinical care and research, which were originally dedicated to improving survival, are now focused on ameliorating quality of life and reducing risk of HIV-related CV disease complications. In high-income countries, over the past decade more emphasis on prevention of atherosclerotic coronary artery disease, including aggressive management of traditional risk factors, as well as earlier initiation of antiretroviral therapy, has reduced risk for myocardial infarction among otherwise healthy people living with HIV infection than obtained in the past. Still, across the globe, adults affected by HIV infection on effective antiretroviral therapy treatment remain at higher risk for coronary events, such as myocardial infarction, than those persons without HIV.

Unique features of HIV-related cardiovascular disease are represented by: 1) the peculiar pathogenesis of coronary disease,

which is often characterized by remodeling ectasia; 2) the unusual morphology of the atherosclerotic plaque; 3) the relative high proportion of type 2 myocardial infarction events; 4) the frequent presence of abnormalities of the aorta (e.g. aneurysms and diffuse aortic inflammation), often associated with a circulating marker of monocyte and macrophage activation². In addition, HIV-related cerebrovasculopathy represents a major contributor to stroke risk in these patients [3].

Here we discuss a case of an adult male affected by HIV presenting with ACS, in whom cardiac magnetic resonance showed some aspects of coronary artery disease which contributed to define prognosis and therapy of patients suffering from HIV infection.

3. Case Presentation

A 54-year-old male, smoker, who was diagnosed as HIV positive 10 years ago and has been on antiretroviral treatment since then, was admitted to the emergency department with a complaint of left-sided chest pain radiating to the left arm. There were no alleviating factors. Upon presentation, vital signs were normal and the physical examination was unremarkable. The 12-lead EKG showed ST elevation in anterior leads (Figure 1a), and serum cardiac biomarkers were increased. Thus, patient was transferred to the cardiac catheterisation lab for urgent percutaneous coronary angiography, which revealed critical stenosis of the left anterior descending ar-

tery (Figure 1b), which was successfully stented. After that, patient was admitted to coronary care unit (CCU), where transthoracic echocardiography revealed akinesia of anterior, septum and apex segments with left ventricle ejection fraction of 25% and a GLS of -8.5%. After three days, cardiac magnetic resonance (CMR) was performed and showed a large ischemic late gadolinium enhancement (LGE) area in anterior, lateral and apical segments with late microvascular obstruction (LMVO) or no-reflow phenomenon, an

established complication of coronary reperfusion therapy for acute myocardial infarction and a recognized poor prognostic indicator and marker of subsequent adverse LV remodeling (Figure 2) [4,5]. Patient performed a cardiopulmonary exercise test (CPET), which resulted in a MAGGIC score6 of 17 points and in a MECKI score 7 of 9.93%. Patient was discharged 7 days since admission with medical treatment for acute myocardial infarction and HAART.

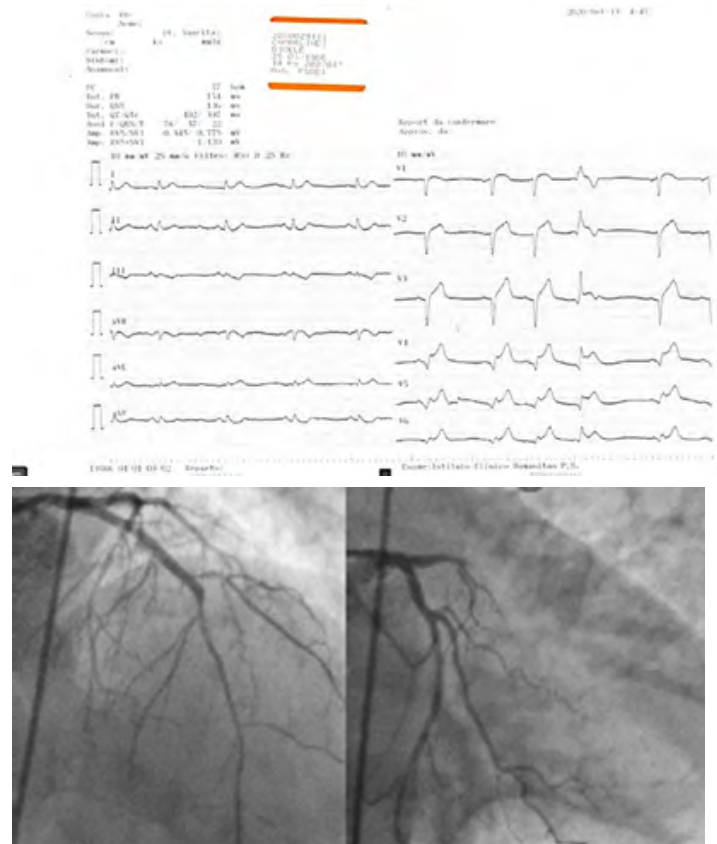


Figure 1 a-b: electrocardiographic and angiographic presentation of acute coronary syndrome

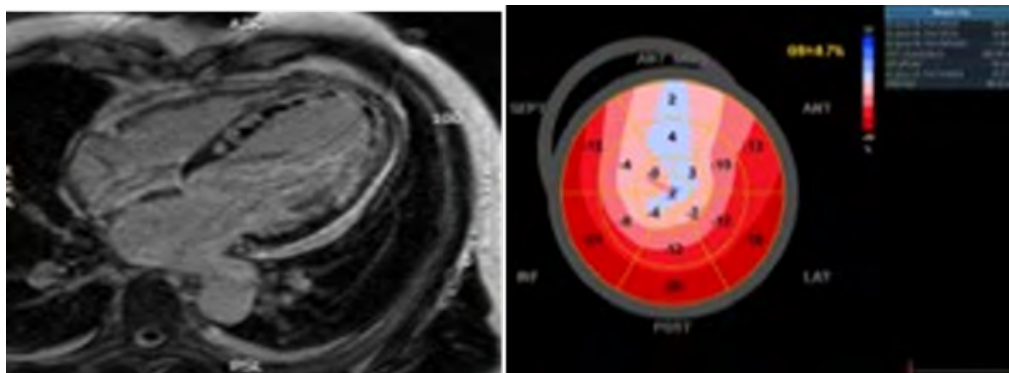


Figure 2: evidence of acute coronary syndrome in cardiac imaging: global longitudinal strain and LGE with LMVO seen with cardiac magnetic resonance

4. Discussion

The chronic infection by HIV is clearly associated, along with the use of certain antiretroviral drugs and traditional risk factors, with an increased risk of CV diseases [8].

Studies performed over the past decade have reflected a shift in prevalence, clinical presentation, and pathophysiological mechanisms underlying the development and progression of HIV-associated acute coronary syndrome (ACS). HIV patients presenting with ACS have increased levels of platelet reactivity 9 and higher prevalence of high residual platelet reactivity (HPR) to P2Y12 inhibitors and aspirin than non- HIV patients [9]. These features might be at least, in part, responsible for the observed increased risk of recurrent ischemic events in HIV population [9]. In the PACS-HIV trial, although the overall risk of major adverse cardiac and cerebrovascular events was not statistically significant between people living with HIV infection (PLHIV) and individuals without HIV infection, PLHIV had a higher rate of recurrent ACS [10]. Furthermore, several clinically relevant drug-to-drug interactions must be considered when co- administering CV drugs and HAART [8].

CMR imaging and autopsy data have emphasized the central importance of intramyocardial fibrosis for the pathogenesis of both heart failure with preserved ejection fraction and the increase in risk of sudden cardiac death. Still, more research is needed to better characterize the underlying mechanisms and clinical phenotype of HIV-associated myocardial disease in the current era. HIV-infected patients, even in subclinical phase, were associated with changes in myocardial function and higher rates of subclinical myocardial inflammation (native T1 relaxation time, ECV value and T2 relaxation time higher) and fibrosis, which were more abnormal with greater severity of the disease [14].

Across the different CV disease manifestations, a common pathogenic feature is that HIV-associated inflammation (Figure 3), seen in subclinical phase with CMR, working through different mechanisms may amplify underlying pathology because of traditional risk and other host factors. The prevalence and phenotype of individual CV disease manifestations is ultimately influenced by the degree of injury from HIV disease combined with the profile of underlying cardiometabolic factors, both of which may differ substantially by region globally [3,11].

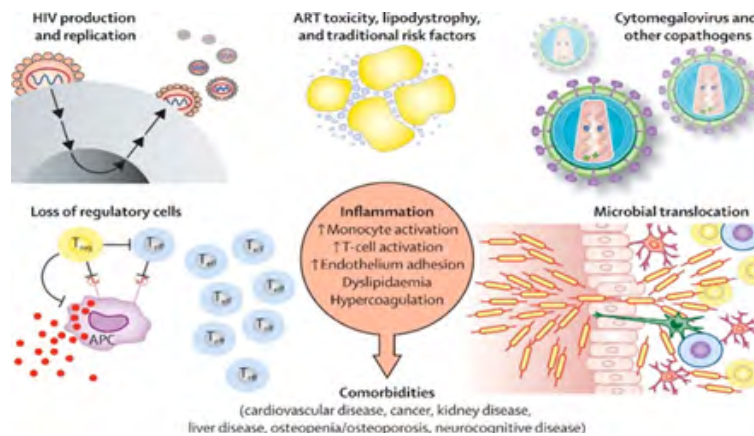


Figure 3: role of inflammation in HIV patients

5. Conclusions

This case illustrates that in people living with human immunodeficiency virus (HIV, PLWH) there is an increased risk of CV disease, especially acute coronary syndrome. HIV infection and accelerated traditional risk factors due to old highly active antiretroviral therapy (HAART) and to the disease are known mechanisms for increased rate of heart failure (HF).

In this population potential strategies, guided by imaging, to reduce the risk of CV disease include targeting traditional risk factors, initiation of antiretroviral therapy to reduce inflammation and other approaches to lower inflammation, including gut-related interventions, statin therapy and immune modulators [12].

Primary and secondary prevention will be a key feature of integrated care: evidence-based interventions considering both pharmacological [13] and non-pharmacological interventions must be prospectively assessed and cost-benefit established.

References

1. Shah ASV, Stelzle D, Lee KK. Global Burden of Atherosclerotic Cardiovascular Disease in People Living With HIV: Systematic Review and Meta-Analysis. *Circulation*. 2018; 138(11): 1100–12.
2. Subramanian S, Tawakol A, Burdo TH. Arterial inflammation in patients with HIV. *JAMA*. 2012; 308(4): 379–86.
3. Ntsekhe M, Baker JV. Cardiovascular disease among persons living with HIV: new insights into pathogenesis and clinical manifestations in a global context. *Circulation*. 2023; 147(1): 83-100.
4. Khafagy RTM, El Mozy W, Hamed E, ElKhalek YIA, Tantawy W. Prognostic value of microvascular occlusion MRI quantification in assessment of reperfused myocardial infarction. *Egypt J Radiol Nucl Med*. 2020; 51(1): 86.
5. Wu KC. CMR of microvascular obstruction and hemorrhage in myocardial infarction. *J Cardiovasc Magn Reson*. 2012; 14: 68.
6. Rich JD, Burns J, Freed BH, Maurer MS, Burkhoff D, Shah SJ, et

- al. Meta-Analysis Global Group in Chronic (MAGGIC) Heart Failure Risk Score: Validation of a Simple Tool for the Prediction of Morbidity and Mortality in Heart Failure with Preserved Ejection Fraction. *J Am Heart Assoc.* 2018; 7(20): e009594.
7. Agostoni P, Corrà U, Cattadori G. Metabolic exercise test data combined with cardiac and kidney indexes, the MECKI score: a multi-parametric approach to heart failure prognosis. *Int J Cardiol.* 2013; 167(6): 2710–8.
 8. Volpe M, Uglietti A, Castagna A. Cardiovascular disease in women with HIV-1 infection. *Int J Cardiol.* 2017; 241: 50–6.
 9. Hauguel-Moreau M, Boccara F, Boyd A, Salem JE, Brugier D, Curjol A, et al. Platelet reactivity in human immunodeficiency virus infected patients on dual antiplatelet therapy for an acute coronary syndrome: the EVERE2ST-HIV study. *Eur Heart J.* 2017; 38(21): 1676-1686.
 10. Boccara F, Mary-Krause M, Potard V. HIV Infection and Long-Term Residual Cardiovascular Risk After Acute Coronary Syndrome. *J Am Heart Assoc.* 2020; 9(17): e017578.
 11. Volpe M, Coluccia R, Battistoni A. What's HIV got to do with cardiovascular disease? *Int J Cardiol.* 2018; 265: 210-1.
 12. Hsue PY, Waters DD. HIV infection and coronary heart disease: mechanisms and management. *Nat Rev Cardiol.* 2019; 16(12): 745–59.
 13. Boccara F, Kumar P, Caramelli B. Evolocumab treatment in patients with HIV and hypercholesterolemia/mixed dyslipidemia: BEIJERINCK study design and baseline characteristics. *Am Heart J.* 2020; 220: 203–12.
 14. Yan C, Li R, Guo X, Yu H, Li W, Li W, et al. Cardiac Involvement in Human Immunodeficiency Virus Infected Patients: An Observational Cardiac Magnetic Resonance Study. *Front. Cardiovasc. Med.* 8: 756162.